

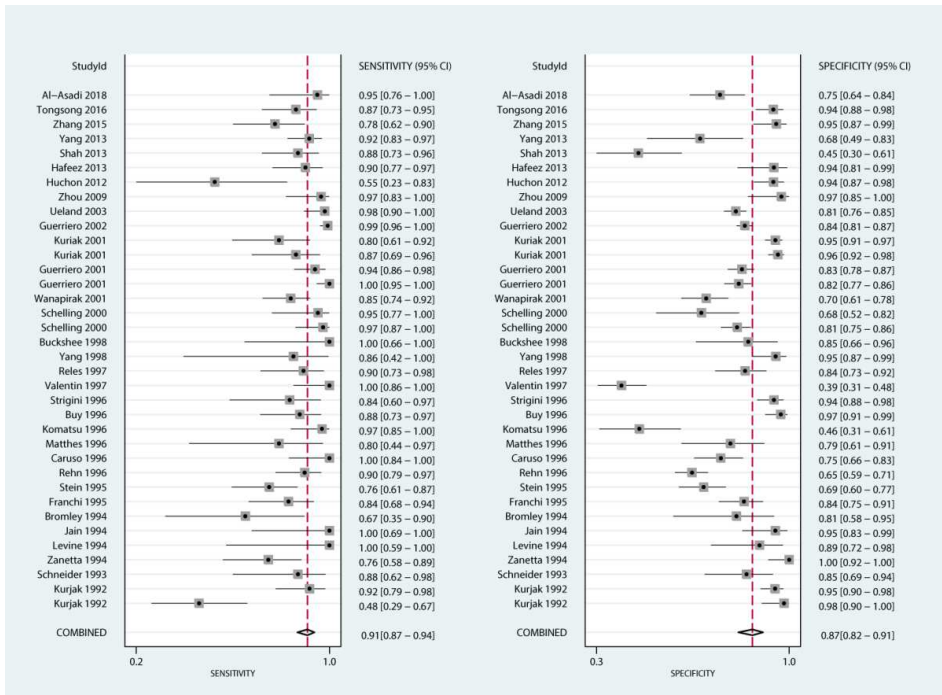Figure S1. The pooled sensitivity and specificity for US differentiate the benign and malignant ovarian masses

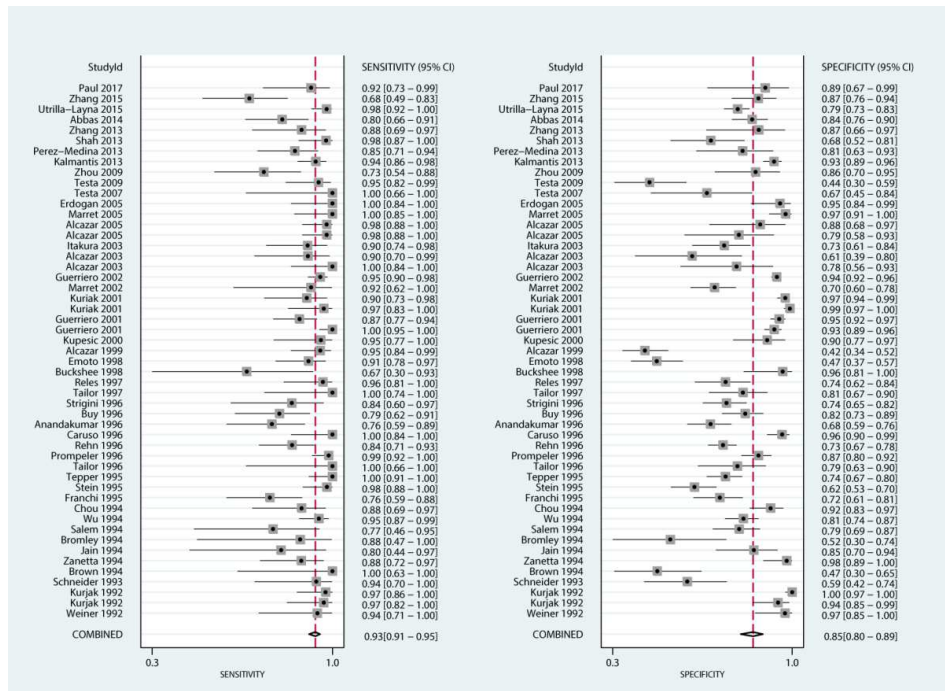


Figure S2. The pooled sensitivity and specificity for Doppler US differentiate the benign and malignant ovarian masses

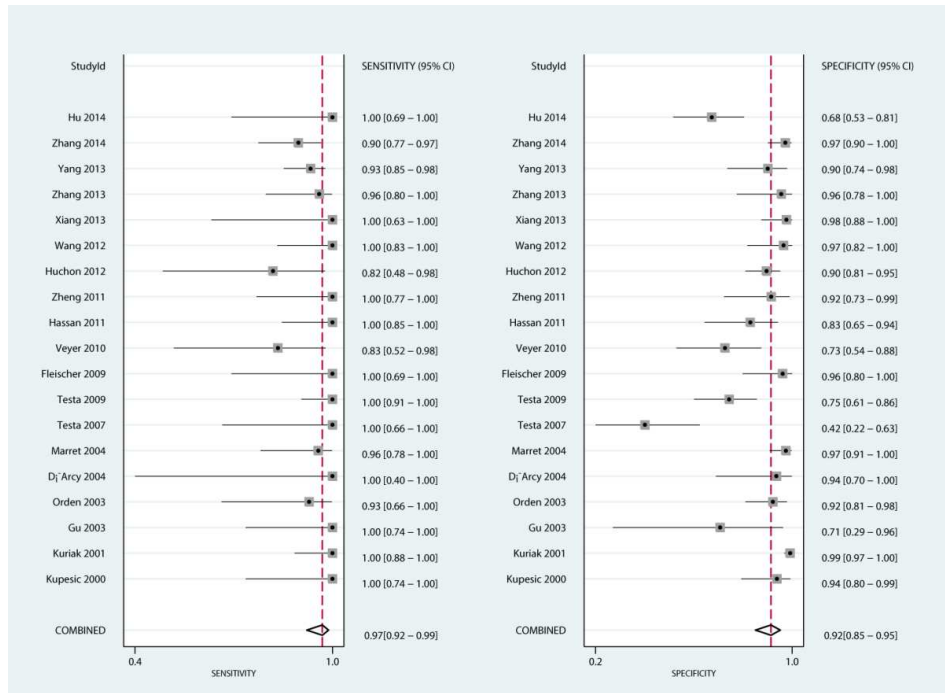


Figure S3. The pooled sensitivity and specificity for CEUS differentiate the benign and malignant ovarian masses