

BMJ Open

BMJ Open is committed to open peer review. As part of this commitment we make the peer review history of every article we publish publicly available.

When an article is published we post the peer reviewers' comments and the authors' responses online. We also post the versions of the paper that were used during peer review. These are the versions that the peer review comments apply to.

The versions of the paper that follow are the versions that were submitted during the peer review process. They are not the versions of record or the final published versions. They should not be cited or distributed as the published version of this manuscript.

BMJ Open is an open access journal and the full, final, typeset and author-corrected version of record of the manuscript is available on our site with no access controls, subscription charges or pay-per-view fees (<http://bmjopen.bmj.com>).

If you have any questions on BMJ Open's open peer review process please email editorial.bmjopen@bmj.com

BMJ Open

The Prostate Cancer Diagnostic Pathway: Reporting a Pilot of a One-Stop Cognitive Magnetic Resonance Imaging Targeted Service

Journal:	<i>BMJ Open</i>
Manuscript ID	bmjopen-2018-024941
Article Type:	Research
Date Submitted by the Author:	04-Jul-2018
Complete List of Authors:	Bass, Edward; Ashford & St Peter's Hospitals Trust, Department of Urology Freeman, Alex; University College London Hospital, Department of Pathology Jameson, Charles; University College London Hospital, Department of Pathology Punwani, Shonit; University College London Medical School, Centre for Medical Imaging Moore, Caroline; University College London, Division of Surgery and Interventional Sciences Arya, Manit; University College London Hospital, Department of Urology Emberton, Mark; University College London, Division of Surgery and Interventional Sciences; University College London Hospital, Department of Urology Ahmed, Hashim; Division of Surgery and Interventional Sciences, University College London
Keywords:	Protocols & guidelines < HEALTH SERVICES ADMINISTRATION & MANAGEMENT, Prostate disease < UROLOGY, Magnetic resonance imaging < RADIOLOGY & IMAGING, Adult urology < UROLOGY

SCHOLARONE™
Manuscripts

The Prostate Cancer Diagnostic Pathway: Reporting a Pilot of a One-Stop Cognitive Magnetic Resonance Imaging Targeted Service

Edward J Bass MBChB [1,2], Alex Freeman FRCPATH [5], Charles Jameson FRCPATH [5], Shonit Punwani FRCR [4], Caroline Moore FRCS (Urol) [1,2], Manit Arya FRCS (Urol) [1,2,6], Mark Emberton FRCS (Urol) [1,2], Hashim U. Ahmed FRCS (Urol) [7,8]

Affiliations

1. Division of Surgery and Interventional Science, University College London, London, UK
2. Department of Urology, University College London Hospitals NHS Foundation Trust, London, UK
3. Centre for Medical Imaging, Division of Medicine, University College London, London, UK
4. Department of Radiology, University College London Hospitals NHS Foundation Trust, London, UK
5. Department of Histopathology, University College London Hospitals NHS Foundation Trust, London, UK
6. Department of Urology, Princess Alexandra Hospital NHS Trust, Harlow, UK
7. Division of Surgery, Department of Surgery and Cancer, Faculty of Medicine, Imperial College London, UK
8. Imperial Urology, Charing Cross Hospital, Imperial College Healthcare NHS Trust, London, UK

Address for correspondence

Mr Edward Bass
St Peters Hospital
Guildford Road
Lyne
Chertsey
KT16 0PZ

Email

Edward.bass@nhs.net

Key words

Transperineal prostate biopsy
Prostate cancer diagnostic pathway
Local Anaesthetic
Targeted prostate biopsy

Abstract word count

216

Manuscript main word count

3230

Abstract

Objectives

To evaluate the suitability and feasibility of a novel multiparametric magnetic resonance imaging (mpMRI) and cognitive fusion transperineal targeted biopsy led prostate cancer (PCa) diagnostic service with regard to cancer detection and reducing time to diagnosis and treatment.

Patients & Methods

Men referred with a raised prostate specific antigen (PSA) or abnormal digital rectal examination (DRE) between 02/2015 and 03/2016 were investigated for PCa. An mpMRI was performed prior to patients attending clinic, on the same day. If required, MRTB was offered. Results were available within 48 hours and discussed at a specialist multidisciplinary team (MDT) meeting. Patients returned for counselling within 7 days.

Results

112 men were referred to the service. 111 (99.1%) underwent mpMRI. Median PSA was 9.4ng/mL [IQR 5.6-21.0]. 87 patients had a target on mpMRI with 25 scoring Likert 3/5 for likelihood of disease, 26 4/5 and 36 5/5.

57 (51%) patients received a local anaesthetic, MRTB. Cancer was detected in 45 (79%). 43 (96%) had University College London (UCL) definition 2 disease or greater. The times to diagnosis and treatment were a median of 8 and 20 days respectively.

Conclusion

This approach greatly reduces the time to diagnosis and treatment. Detection rates of significant cancer are high. Similar services may be valuable to patients with a potential diagnosis of PCa.

Strengths and limitations of this study

- First prospective study demonstrating the clinical feasibility of a 'one stop', rapid diagnostic prostate cancer pathway, using both multiparametric magnetic resonance imaging and transperineal targeted biopsy.
- Inclusion criteria reflecting 'real world' practice in the United Kingdom.
- This study incorporates a standardised multiparametric MRI acquisition and a validated system for defining clinically significant prostate cancer.
- Cognitive targeted biopsy performed only, rather than mpMRI / ultrasound fusion.
- Transperineal, rather than transrectal approach offers minimal septic complications post biopsy.

Introduction

Accurate risk stratification for men presenting with localised prostate cancer is vitally important. In its absence, patient centred management cannot be offered. Men with low-risk disease can be safely managed with active surveillance, whereas men with a good life expectancy and intermediate to high-risk disease are likely to benefit from interventional treatment[1-2]. Currently, standard practice uses prostate-specific antigen (PSA) value, digital rectal examination (DRE) and transrectal ultrasound guided biopsy (TRUSGB). However, TRUSGB is inherently random. The tumour cannot be visualised with certainty, and thus leads to overdiagnosis of insignificant disease in up to 50% of men[3], and missing significant disease in 18% of men, especially if cancer is located in anterior or apical regions of the prostate[4]. This creates difficulty for urologists and adds anxiety to patients[5] who have to undergo a repetitive cascade of diagnostic tests, which inevitably has cost implications for healthcare providers.

Transperineal mapping or zonal biopsies (TPM) of the prostate offer a diagnostic alternative to TRUS biopsy with demonstrable diagnostic success. However, the burden on patients is high. Firstly, the extensive biopsies demand general anaesthesia. Secondly, the rates of urinary retention following the procedure are

1
2
3 high, making postoperative catheterization commonplace. Thirdly, the large number
4 of cores taken requires many hours of labour to assess. Thus, a patient may have to
5 wait significantly longer for a result, adding to their anxiety. This may also delay
6 necessary treatment. Whether this results in adverse outcomes is not known.
7
8 However, all of these established difficulties do confer added costs. Indeed, if every
9 patient undergoing TRUSGB instead underwent a TPM, the cost of such a move
10 would likely be exceedingly high. Therefore, the challenge presents itself as biopsy
11 offering superior clinically significant detection rates to the existing standard, whilst
12 not conferring an added cost.
13
14
15
16
17
18

19 Multiparametric magnetic resonance imaging (mpMRI) of the prostate has proved a
20 useful tool in the diagnosis and risk stratification of prostate cancer. MpMRI has
21 demonstrated its ability to detect significant cancers, whilst not detecting those
22 which are insignificant[4]. Suspicious areas on mpMRI can be targeted with
23 subsequent transperineal biopsy (MRTB). MRTB has demonstrated greater sampling
24 efficiency and accuracy when compared with standard TRUS-guided protocols[6-8],
25 and has demonstrated accuracy when compared to the reference standard of radical
26 prostatectomy (RP)[9]. This allows for a more accurate assessment of Gleason
27 grade, and therefore an improved risk stratification and treatment plan at
28 diagnosis[10]. Furthermore, the efficiency advantage, i.e. taking fewer cores at
29 biopsy, confers significant benefits in cost, patient tolerability and post biopsy sepsis
30 rates.
31
32
33
34
35
36
37
38
39

40 Three methods of transperineal MRTB currently exist. First and most common is
41 'cognitive targeting'. This approach requires the urologist to review the mpMRI
42 images and aim the needle toward the corresponding area on ultrasound (US)
43 imaging[11]. Alternatively, the reporting urologist draws a diagrammatic
44 representation of the gland and any suspicious area contained within, which guides
45 the urologist to potential cancer. Second, 'in-bore MRTB' is performed whilst the
46 patient is in the MRI scanner, allowing for real time targeting of suspicious areas
47 with MRI compatible biopsy equipment. Third, 'fusion targeting' uses specifically
48 designed software to allow combination of the mpMRI images with real time US
49 imaging[4]. The latter two methods have implications in terms of equipment
50
51
52
53
54
55
56
57
58
59
60

1
2
3 availability and cost, and as of yet the question of superiority of any one over
4 another remains elusive[4].
5

6
7 Currently, prostate cancer diagnostic pathways remain built around TRUSGB.
8 MpMRI is more commonly being used prior to TRUSGB. However, the use of an
9 mpMRI and MRTB pathway remains a rarity despite the potential advantages of such
10 an approach. The reasons for this are multiple and commonly relate to the
11 techniques being in their relative infancy. The lack of standardised mpMRI
12 reporting[12], a learning curve for operators[13], mpMRI availability and cost[14]
13 and concern regarding missed diagnosis from not sampling the whole gland have all
14 been cited as reasons not to accept widespread adoption. Despite this, MRI-guided
15 targeted biopsy pathways have been utilised before, albeit via the transrectal rather
16 than the transperineal route[15-17]. The recent findings of the PRECISION [18] trial
17 has clearly addressed concerns in regard to superiority of an MRI-targeted biopsy
18 approach over systematic TRUS biopsy, demonstrating superiority in clinically
19 significant cancer detection rate and a reduction in the detection of insignificant
20 disease.
21

22 Thus, the objective of this study was primarily to determine the suitability and
23 feasibility of a transperineal MRI-targeted biopsy pathway for prostate cancer in
24 'real-world' clinical practice. Outcome measures in this regard included the time to
25 diagnosis and treatment of patients referred with a suspicion of prostate cancer.
26 Quality control outcome measures included clinically significant and total cancer
27 detection rates.
28
29
30
31

32 **Patients and Methods**

33
34 This prospective study analyses the clinical and service outcomes of an mpMRI and
35 MRTB led prostate cancer diagnostic pathway (*figure 1*) from 02/2015 to 03/2016.
36 Inclusion criteria were men presenting with a biochemical or clinical suspicion of
37 prostate cancer under the United Kingdom two week wait program and undergoing
38 mpMRI and if necessary subsequent cognitive targeted prostate biopsy. Patients
39
40
41
42
43
44
45
46
47
48
49
50
51
52
53
54
55
56
57
58
59
60

1
2
3 without negative urine cultures or with estimated glomerular filtration rates of <30
4 micromol/L were excluded. The patient was contacted on referral and an mpMRI
5 was arranged. This was reported before the patient attended clinic in the early
6 afternoon of the same day. If a targetable lesion was identified (Likert ≥ 3), a
7 transperineal-targeted biopsy was offered. Results were available within 48 hours
8 and were discussed at a specialist MDT. Patients returned for counselling within
9 seven days.

10
11
12
13
14
15
16 MpMRI acquisition was performed according to the European guidelines of Uro-
17 radiology previously described by the University College London (UCL)
18 group[12,19,20]. In summary this includes the use of a 1.5 or 3.0 Tesla MRI scanner
19 acquiring T2-weighted axial and coronal, axial diffusion weighted coefficient and
20 high *b*-value as well as T1 weighted dynamic contrast enhancement (intravenous
21 Gadolinium) images. Each scan was reported by an experienced uro-radiologist as
22 previously described [21,22] and a pictorial diagrammatic map drawn (*figure 2*).
23 Regions of interest (ROIs) were scored using a Likert-like scale of 1-5[22] using the
24 overall impression of the radiologist to characterise the level of suspicion for
25 prostate cancer. ROIs scoring 4 or 5 were thought 'likely' or 'highly likely' to contain
26 a malignant lesion, which was either ≥ 0.2 mL in volume and/or had high-grade
27 components within (Gleason $\geq 3+4$)[23]. ROIs 3 were rated as indeterminate for such
28 disease and this score of 3, or higher, was chosen as the threshold for a positive
29 mpMRI. Our choice of scoring system was based on the outcomes of the 2011
30 European Consensus Meeting[12] which met prior to the Prostate Imaging and Data
31 Reporting System (PIRADS) MP-MRI reporting consensus meeting[19] and has
32 demonstrated equivalency with the PIRADS system[24].

33
34
35
36
37
38
39
40
41
42
43
44
45
46
47
48
49
50
51
52
53
54
55
56
57
58
59
60
The procedure was performed as a day case under local anaesthesia and
antimicrobial prophylaxis in the lithotomy position, by either a consultant urologist
or urology clinical fellow as previously described[25]. This biopsy technique has
demonstrated a median procedure length of 30 minutes and good patient toleration,
with median visual analogue pain scores of 1.0[26].

Data was collected on a case report form compliant with the Standards of Reporting

for MRI-targeted Biopsy Studies (START) of the prostate[11]. Included data were patients demographics, indications for biopsy, PSA value, prostate volume, number of targets per patient, and Likert score per target[11]. Additionally, for each biopsy collected the total number of cores taken, biopsy density, number of positive cores, maximum and overall Gleason scores and the maximum cancer core length (MCCL). Biopsy efficiency was calculated by the number of cores demonstrating clinically significant disease divided by the number of cores taken. For the purpose of this study, clinically significant disease was defined using the University College London (UCL) classification for interpreting transperineal biopsy findings, which sets the significance threshold at Gleason score \geq to 3 + 4 and/or MCCL \geq 4 mm for definition 2 and \geq to 4 + 3 and/or MCCL \geq 6 mm for definition 1[26] (figure 3).

Finally, to assess the time to diagnosis and treatment as well as the treatments elected by men were determined by examination of the hospital trust's electronic data system.

Patient and Public Involvement

This study received approval from the local audit committee. An informative consent process was performed for each patient prior to biopsy.

Results

Table 1

A. Patient Demographics		
Men included		112
Median Age (years)		68 [IQR 62-78]
Median PSA (ng/mL)		9.4 (IQR 5.6 - 21.0)
B. MpMRI Outcomes		
	n	%
Men undertaking mpMRI	111	99%
Median Prostate Volume (mL)	50 (IQR 35 - 78)	
Positive mpMRI (Men)	87	78%
Negative mpMRI (Men)	24	22%
Total ROIs	162	

1 ROIs / man	39	35%		
2 ROIs / man	25	23%		
3 ROIs / man	22	20%		
4 ROIs / man	1	1%		
<i>Likert score per man</i>				
Likert 3	25	23%		
Likert 4	26	23%		
Likert 5	36	32%		
Total ROIs	162			
Median ROI volume (mL)	0.5 (IQR 0.2 - 1.0)			
<i>Likert score per lesion</i>				
Likert 3	71	44%		
Likert 4	49	30%		
Likert 5	42	26%		
C. Biopsy Outcomes				
	n	%		
Men undertaking biopsy	57	51%		
Median cores per patient	9 (IQR 5 - 12)			
Total cores	514			
Cores positive (UCL 2)	241	47%		
Biopsy efficiency	47%			
Median cores per lesion	4 (IQR 4 - 5)			
Median biopsy density (cores / ROI mL)	10 (IQR 3.5 - 20)			
Cancer detection by man				
Any Cancer	45	79%		
UCL 2	43	75%		
UCL 1	34	60%		
Gleason $\geq 3+4$	43	75%		
Gleason $\geq 4+3$	23	40%		
Median MCCL (mm)	7 (IQR 3 - 10)			
Cancer detection by lesion				
Likert 3 (lesions biopsied)	40	13	10	4
Likert 4 (lesions biopsied)	38	24	19	15
Likert 5 (lesions biopsied)	35	35	35	28
D. Diagnosis and Treatment Outcomes				
Median time to diagnosis (days)	8 (IQR 5 - 12)			
Median time to treatment (days)	20 (IQR 8 - 40)			

<i>Treatment type (Post Biopsy)</i>	n	%
Discharged	4	7%
PSA Surveillance	6	11%
Active Surveillance	5	9%
Focal therapy	6	11%
Robotic Prostatectomy	9	16%
External Beam Radiotherapy	10	18%
Brachytherapy	2	4%
Androgen Deprivation Therapy	9	16%
Chemotherapy	4	7%
Antibiotics	1	2%
Repeat biopsy	1	2%

Patient demographics

In total, 112 consecutive biopsy naive men with a median age of 68 attended the prostate cancer one stop clinic between 02/2015 and 03/2016 (*Table 1A*). All but one man (99%) received an mpMRI scan prior to clinic. The patient in question had an MRI incompatible cardiac pacemaker.

MpMRI Outcomes

The median prostate volume was 50mL. Eighty-seven men (78%) had a positive mpMRI (Likert score ≥ 3) and 24 (22%) had a negative scan (Likert score ≤ 2) and did not go on to biopsy. Twenty-five men (29%) had an mpMRI scan with an overall Likert score of 3, 26 (30%) an overall score of 4 and 36 (41%) an overall Likert score of 5. There were 162 ROIs identified on mpMRI with a median volume of 0.5mL when measured on T2 MRI sequencing. Thirty-nine men (45%) had a single ROI on mpMRI, 25 men (29%) had two, 22 men (25%) had three and a single man (1%) had four. Seventy-one lesions (30%) were Likert 3, 49 (30%) at Likert 4 and 42 (26%) and Likert 5. After mpMRI, nine with negative mpMRIs (38%) were discharged for PSA surveillance in the community, 10 (42%) remained on PSA surveillance in secondary care, four (17%) underwent investigations for lower urinary tract symptoms and one (4%) underwent a full template biopsy under general anaesthetic (*Table 1B*).

Biopsy Outcomes

1
2
3 Fifty-seven men (51%) underwent a local anaesthetic MRTB as described following
4 mpMRI (*Table 1C*). Fifteen (17%) men chose not to undergo biopsy under local
5 anaesthetic and were listed for a biopsy under sedation. Thirteen men (15%) did not
6 have a biopsy due to clinical reasons. Any cancer was detected in 45 (79%) of men.
7
8 Of these, 43 (96%) satisfied the UCL 2 criteria for clinical significance and 34 (76%)
9 satisfying the UCL 1 criteria. The median MCCL of positive biopsies was 7mm. The
10 calculated biopsy efficiency for UCL 2 disease was 47%. The median number of cores
11 taken per ROI was 4, with a median calculated biopsy density of 10 cores/mL of ROI.
12
13 Of the 20 men who had more than one lesion on mpMRI and underwent biopsy, two
14 had a secondary lesion, which harboured either higher grade or volume disease. In
15 only one of these men was the secondary lesion a lower Likert score. Both such men
16 went on to radical prostatectomy.
17
18
19
20
21
22
23
24
25
26

27 ***Diagnosis and Treatment Outcomes***

28
29 The median time to a man being told his diagnosis was eight days, and the median
30 time by which treatment had been started was 20 days, although in five cases this
31 time period was not clear (*Table 1D*). The treatment outcomes are shown in table
32 1D. Of note, 20 (18%) men were discharged after biopsy with 19 (17%) men starting
33 PSA surveillance. Forty-four (40%) went on to undergo treatment and nine (8%) men
34 underwent a further biopsy either due a perceived false negative or diffuse disease
35 requiring a biopsy under sedation or general anaesthetic. Eleven (10%) patients
36 underwent further assessment or treatment for benign disease.
37
38
39
40
41
42
43

44 **Discussion**

45
46 An optimal PCa diagnostic strategy should encapsulate maximal significant cancer
47 detection whilst avoiding insignificant disease or repeat biopsy. Furthermore, it
48 should convey enough information for urologists and patients to accurately devise a
49 treatment plan according to the risk of progression. However, as things stand, the
50 diagnostic pathway is still commonly led by TRUSGB, despite its accepted inaccuracy,
51 especially for disease located in the anterior or apical regions of the prostate[27]. In
52
53
54
55
56
57
58
59
60

1
2
3 particular the negative predictive value (NPV) of the originally described six core
4 TRUSGB is poor, with false negative rates of around 35%[28,29]. This inherent
5 disadvantage is somewhat mitigated by extending the biopsy to a 12 or even 24 core
6 technique, however increasing the number of cores past 12 leads to increased
7 numbers of insignificant cancers being detected[30,31] which is present in 40% of
8 men over the age of 50[32]. These cancers are rarely affect life expectancy or its
9 quality in any meaningful way and revealing them simply adds unnecessary burdens
10 to patients. Furthermore, increasing the number of cores may increase incidence of
11 post TRUSGB sepsis[33] and with the incidence already on the rise alongside
12 increasing prevalence of colonisation with resistant organisms such strategies pose
13 an increasing potential for harm[34] for which our clinical options are worryingly
14 limited. As a result, transperineal zonal or mapping biopsies (TPM) have become
15 more popular. In particular, one recent series reported a 0% readmission rate for
16 infective complications after targeted transperineal biopsy[35], in comparison to
17 rates of sepsis of up to 6.3% after TRUSGB[36]. However, there are significant
18 concerns regarding its cost, need for general anaesthetic, increased complications
19 and patient burden. Such concerns have justly prevented its wider use and certainly
20 a TPM led diagnostic pathway has not been seriously suggested.

21
22
23
24
25
26
27
28
29
30
31
32
33
34
35 However, the development and refinement of mpMRI demands that its use in
36 leading an approach to diagnosis must be contemplated. MpMRI has demonstrated
37 high levels of accuracy for the detection of clinically significant cancer when
38 compared to both TPM[37] and whole-mount prostatectomy specimens[9]. Indeed,
39 a systematic review by Fütterer et al found that mpMRI detected clinically significant
40 disease in up to 84% of men with a NPV of up to 98% where either TPM or
41 prostatectomy was used as the reference standard[20]. More recently the results of
42 the PROMIS trial demonstrate the sensitivity and negative predictive value of mpMRI
43 in detecting clinically significant disease as 93% and 89% respectively[38].
44 Furthermore, the PROMIS trial demonstrated that 27% of men could avoid a
45 biopsy[38]. Despite these findings, both the European Association of Urology
46 (EAU)[39] and National Institute of Clinical Excellence (NICE)[40] still do not
47 recommend mpMRI prior to an initial set of biopsies. In this study, leading with
48
49
50
51
52
53
54
55
56
57
58
59
60

1
2
3 mpMRI allowed 24 (21.6%) men to avoid a biopsy entirely. However, the majority
4 would remain on PSA surveillance due to the small – but understood - risk of a false
5 negative mpMRI. There is perhaps a concern that in less experienced centres
6 overcall images as PIRADS 3 is an issue that will expose men to unnecessary biopsies
7 and thus reducing the benefit of an image-guided pathway. However, as the PIRADS
8 v2[41] scoring system is increasingly adopted, with its ability to define a PIRADS 4
9 lesion over a 3 by utilisation of the second parameter (DCE and DWI for peripheral
10 zone and transition zone lesions respectively), alongside its more easily understood
11 and applicable design, should reduce such an effect going forward.
12
13
14
15
16
17
18

19 Clearly, there is enough evidence now to introduce an image-guided biopsy to the
20 PCa diagnostic pathway, bringing it in line with the current practice in other solid
21 organ malignancies. However, currently there is concern that targeted biopsies
22 alone risk missing areas of significant disease that appear normal on mpMRI. This
23 may be viewed as a limitation. However, our current approach to this cohort of men
24 was introduced after our paired analyses of mpMRI versus template biopsies
25 demonstrated that mpMRI cognitive biopsies had equivalent detection rates to zonal
26 mapping biopsies[37]. Furthermore, numerous centres have now reported
27 improved cancer detection rates of MRTB strategies when compared to systematic
28 approaches [42,43], as well as improved biopsy efficiency and reduced false negative
29 rates for significant cancer[8]. To underline this, another series of men who
30 underwent both fusion MRTB and systematic TPM showed a difference of clinically
31 significant cancer detection rates of 4% (28% for MRTB and 24% for systematic
32 biopsy), although combined biopsies outperformed each approach in isolation[44].
33 Naturally, such results have been reported by specialist centres and as such, concern
34 remains in regard to the level of operator dependency with targeted biopsy
35 techniques. However, authors have found no difference between cancer detection
36 rates with targeted techniques regardless of the experience of the operator, albeit
37 with TRUSGB[45].
38
39
40
41
42
43
44
45
46
47
48
49
50
51

52 As with mpMRI, MRTB is not a perfect test, both can miss significant disease.
53 However, this is an improvement on our current standard diagnostic test which is
54 demonstrably poor[27-30]. As recent studies have shown, in comparison to TRUSGB,
55
56
57
58
59
60

1
2
3 MRTB is more likely to detect disease once a suspicious area has been
4 identified[6,17]. Furthermore, the recently published PRECISION randomised
5 controlled trial clearly demonstrated the superior clinically significant cancer
6 detection rate of MRTB and a reduced insignificant cancer detection rate when
7 compared to systematic TRUS biopsy[18].
8
9

10
11
12 A potential limitation of the MRTB technique in this study is the use of ‘cognitive
13 fusion’ rather than US/mpMRI fusion or ‘in-bore’ targeting. However, no superiority
14 of one technique over another has been clearly demonstrated, whilst ‘cognitive
15 fusion’ is clearly a less costly option[46]. Another potential limitation of the targeted
16 biopsy strategy is the ‘satisfaction of search’ bias. Essentially, this means that after
17 the primary lesion is scored, less attention to detail is given to subsequent lesions,
18 which may therefore be undercalled or undersampled. However, in this series this
19 occurred twice, only once where the secondary lesion was attributed a lower score
20 than the primary, and in no cases did this change the proposed management.
21 Further, in the vast majority of centres where radical treatments – rather than focal
22 – remain the standard of care, there would likely be no change in the approach to
23 curative therapy, save for planning for prostatectomy in the case of nerve-sparing
24 procedures.
25
26

27
28
29 The cost of mpMRI has been cited as a reason for persisting with TRUSGB led
30 diagnostic pathways [47], using it instead for a second investigation in the case of a
31 negative biopsy in a patient in whom suspicion of cancer remains. Whilst mpMRI is
32 indeed useful in this scenario, recent cost effectiveness analyses have shown the
33 long term cost benefits of mpMRI led pathways when various outcomes are
34 accounted for[14,48,49] due to a reduction in overdiagnosis and higher detection
35 rates of clinically significant disease at primary biopsy. In particular, the cost-analysis
36 of the PROMIS trial cohort demonstrated that MpMRI first followed by two MRTBs
37 detects more cancer per pound spent than a TRUS first biopsy strategy[49].
38
39

40
41
42 A major advantage of our pathway is the low time to diagnosis and treatment. At a
43 median of 8 and 20 days respectively the time a patient waits is significantly below
44 the 31 and 62-day targets set by the United Kingdom National Health Service. The
45
46
47
48
49
50
51
52
53
54
55
56
57
58
59
60

1
2
3 meeting of these targets is a persistent challenge nationally[50]. Moreover,
4 performing an mpMRI prior to primary biopsy negates the risk of an initial false
5 negative biopsy significantly delaying a subsequent mpMRI due to post biopsy
6 haemorrhage within the prostate. This makes it difficult to localise cancer or
7 accurately determine its size or border[51]. In such circumstances, the delay in
8 diagnosis can be up to eight weeks.
9
10
11
12
13
14
15

16 **Conclusions**

17
18 This novel pathway offers an alternative to standard prostate cancer diagnostic
19 services. Attendance and cancer detection rates are high. The use of an mpMRI led
20 pathway allows for a significant proportion of men to avoid a biopsy and for those
21 who do, the time to diagnosis and definitive treatment is kept particularly low. The
22 integration of both mpMRI and MRTB in the prostate cancer diagnostic pathway has
23 shown cost-effectiveness in the long-term. This is especially true where rapid
24 diagnostics are mandated or desirable. Furthermore, today, where septic
25 complications are of grave concern, the transperineal route is particularly
26 advantageous. This pilot study demonstrates, that similar services can be provided in
27 appropriate centres and may be valuable to patients with a potential diagnosis of
28 prostate cancer
29
30
31
32
33
34
35
36
37
38
39
40
41
42
43
44
45
46
47
48
49
50
51
52
53
54
55
56
57
58
59
60

41 **Contributorship statement**

42 Edward J Bass drafted the manuscript and approved the final version.

43
44 Alex Freeman contributed to the conception of the work presented, revised the
45 manuscript critically and approved the final version.

46
47 Charles Jameson contributed to the conception of the work presented and revised
48 the manuscript critically and approved the final version.

49
50 Shonit Punwani contributed to the conception of the work presented and revised
51 the manuscript critically and approved the final version.
52
53
54
55
56
57
58
59
60

1
2
3 Caroline Moore contributed to the conception of the work presented and revised
4 the manuscript critically and approved the final version.
5

6
7 Manit Arya revised the manuscript critically and approved the final version.
8

9
10 Mark Emberton contributed to the conception of the work presented and revised
11 the manuscript critically and approved the final version.
12

13
14 Hashim U. Ahmed contributed to the conception of the work presented and revised
15 the manuscript critically and approved the final version.
16

17
18 All authors are accountable for all aspects of the work in terms of accuracy and
19 integrity.
20
21
22
23
24

25 **Competing Interests**

26
27 Hashim Ahmed's research is supported by core funding from the United Kingdom's
28 National Institute of Health Research (NIHR) Imperial Biomedical Research
29 Centre. This paper is independent research funded by the National Institute for
30 Health Research (NIHR) Imperial Biomedical Research Centre (BRC). The views
31 expressed in this publication are those of the author(s) and not necessarily those of
32 the NHS, the National Institute for Health Research or the Department of Health.
33
34
35

36
37 Ahmed currently receives funding from the Wellcome Trust, Prostate Cancer UK,
38 Sonacare Inc., Trod Medical and Sophiris Biocorp for trials in prostate cancer. Ahmed
39 is a paid medical consultant for Sophiris Biocorp for trials work.
40
41
42
43

44
45 Mark Emberton's research is supported by core funding from the United Kingdom's
46 National Institute of Health Research (NIHR) UCLH/UCL Biomedical Research
47 Centre. He was awarded NIHR Senior Investigator in 2015.
48
49

50
51 Emberton receives funding from NIHR-i4i, MRC, Sonacare Inc., Trod Medical, Cancer
52 Vaccine Institute and Sophiris Biocorp for trials in prostate cancer. Emberton is a
53 medical consultant to Sonacare Inc., Sophiris Biocorp, Steba Biotech, Exact Imaging
54 and Profound Medical.
55
56
57
58
59
60

1
2
3 Moore receives funding from the National Institute for Health Research, The
4 European Association of Urology Research Foundation, Prostate Cancer UK,
5 Movember and the Cancer Vaccine Institute, for clinical prostate cancer research.
6 She has received advisory board fees for Genomic Health.
7
8
9

10 Ahmed, Emberton, and Moore are all proctors for HIFU and are paid for training
11 other surgeons in this procedure.
12
13

14 Emberton and Freeman have loan notes/stock options in Nuada Medical Ltd (UK).
15
16
17
18
19

20 **Funding**

21 This research received no specific grant from any funding in the public, commercial
22 or not-for-profit sectors.
23
24
25
26
27
28
29

30 **Data sharing statement**

31 Supplementary data is available in the reference tables in the appendix.
32
33
34
35
36
37

38 **References**

- 39 1. Wilt TJ, Brawer MK, Jones KM, Barry MJ, Aronson WJ, Fox S, et al. Radical
40 prostatectomy versus observation for localized prostate cancer. *N Engl J Med*
41 2012; 367: 203–13.
42
- 43 2. Klotz L, Vesprini D, Sethukavalan P, Jethava V, Zhang L, Jain S, et al. Long-term
44 follow-up of a large active surveillance cohort of patients with prostate
45 cancer. *J Clin Oncol* 2015; 33: 272–7.
46
- 47 3. Loeb S, Bjurlin MA, Nicholson J, Tammela TL, Penson DF, Carter HB et al.
48 Overdiagnosis and overtreatment of prostate cancer. *Eur Urol* 2014; 65: 1046
49
- 50 4. Puech P, Rouviere O, Renard-Penna R, Villers A, Devos P, Colombel M et al.
51
52
53
54
55
56
57
58
59

1
2
3 Prostate cancer diagnosis: multiparametric MR-targeted biopsy with
4 cognitive and transrectal US-MR fusion guidance versus systematic biopsy—
5 prospective multicenter study. *Radiology* 2013; 268: 461
6
7

- 8
9
10
11
12
13
14
15
16
17
18
19
20
21
22
23
24
25
26
27
28
29
30
31
32
33
34
35
36
37
38
39
40
41
42
43
44
45
46
47
48
49
50
51
52
53
54
55
56
57
58
59
60
5. Brocken P, Prins JB, Dekhuijzen PN & van der Heijden HF. The faster the better?—A systematic review on distress in the diagnostic phase of suspected cancer, and the influence of rapid diagnostic pathways. *Psychooncology* 2012; **21**(1): 1-10
 6. Moore CM, Robertson NL, Arsanious N, Middleton T, Villers A, Klotz L, et al. Image-guided prostate biopsy using magnetic resonance imaging-derived targets: a systematic review. *Eur Urol* 2013; 63: 125–40.
 7. Siddiqui MM, Rais-Bahrami S, Turkbey B, George AK, Rothwax J, Shakir N, et al. Comparison of MR/ultrasound fusion-guided biopsy with ultrasound-guided biopsy for the diagnosis of prostate cancer. *J Am Med Assoc* 2015; 313: 390–7.
 8. Schoots IG, Roobol MJ, Nieboer D, Bangma CH, Steyerberg EW, Hunink MG. Magnetic resonance imaging-targeted biopsy may enhance the diagnostic accuracy of significant prostate cancer detection compared to standard transrectal ultrasound-guided biopsy: a systematic review and meta-analysis. *Eur Urol* 2015; 68(3): 438-50
 9. Puech P, Potiron E, Lemaitre L, Leroy X, Haber GP, Crouzet S et al. Dynamic contrast-enhanced-magnetic resonance imaging evaluation of intraprostatic cancer: correlation with radical prostatectomy specimens. *Urology* 2009; 74: 1094
 10. Hambrock T, Hoeks C, Hulsbergen-van de Kaa C, Scheenen T, Fütterer J, Bouwense S et al. Prospective assessment of prostate cancer aggressiveness using 3-T diffusion-weighted magnetic resonance imaging-guided biopsies versus a systematic 10-core transrectal ultrasound prostate biopsy cohort. *Eur Urol* 2012; 61:177

11. Moore CM, Kasivisvanathan V, Eggener S, Emberton M, Fütterer JJ, Gill IS et al. Standards of reporting for MRI-targeting biopsy studies (START) of the prostate: recommendations from an International Working Group. *Eur Urol* 2013; 63: 544
12. Dickinson L, Ahmed HU, Allen C, Barentsz JO, Carey B, Fütterer JJ et al. Magnetic resonance imaging for the detection, localization, and characterization of prostate cancer: recommendations from a European consensus meeting. *Eur Urol* 2011; 59: 7477
13. Gaziev G, Wadhwa K, Barrett T, Koo BC, Gallagher FA, Serrao E et al. Defining the learning curve for multiparametric magnetic resonance imaging (MRI) of the prostate using MRI-transrectal ultrasonography (TRUS) fusion-guided transperineal prostate biopsies as a validation tool. *BJU Int* 2016; 117: 80-86
14. De Rooij M, Crienen S, Witjes JA, Barentsz JO, Rovers MM, Grutters JP. Cost-effectiveness of magnetic resonance (MR) imaging and MR-guided targeted biopsy versus systematic transrectal ultrasound-guided biopsy in diagnosing prostate cancer: a modeling study from a health care perspective. *Eur Urol* 2014; 66: 430-436
15. Venderink W, van Luijckelaar A, Bomers JG, van der Leest M, Hulsbergen-van de Kaa C, Barentsz JO et al. Results of Targeted Biopsy in Men with Magnetic Resonance Imaging Lesions Classified Equivocal, Likely or Highly Likely to Be Clinically Significant Prostate Cancer. *Eur Urol* 2017 [cited 2018 Feb 9]. Available from: <https://www.ncbi.nlm.nih.gov/pubmed/28258784>
16. Nassiri N, Natarajan S, Margolis DJ & Marks LS. Targeted Prostate Biopsy: Lessons Learned Midst the Evolution of a Disruptive Technology. *Urology* 2015; 86(3): 432-438
17. Pokorny MR, de Rooij M, Duncan E, Schroder FH, Parkinson R, Barentsz JO et al. Prospective study of diagnostic accuracy comparing prostate cancer detection by transrectal ultrasound-guided biopsy versus magnetic resonance

- (MR) imaging with subsequent MR-guided biopsy in men without previous prostate biopsies. *Eur Urol* 2013; **66**: 22
18. Kasivisvanathan V, Ranniko AS, Borghi M, Panebianco V, Mynderse LA, Vaarala MH. MRI-Targeted of Standard Biopsy for Prostate-Cancer Diagnosis. *N Engl J Med* 2018. 378(19): 1767-1777.
19. Barentsz JO, Richenberg J, Clements R, Choyke P, Verma S, Villeirs S et al. ESUR prostate MR guidelines 2012. *Eur Radiol* 2012; **22**(4): 746-57
20. Kasivisvanathan V, Dufour R, Moore CM, Ahmed HU, Abd-Alazeez M, Charman SC, et al. Transperineal magnetic resonance image targeted prostate biopsy versus transperineal template prostate biopsy in the detection of clinically significant prostate cancer. *J Urol* 2013; 189:860–6.
21. Fütterer JJ, Briganti A, De Visschere P, Emberton M, Giannarini G, Kirkham A et al. Can Clinically Significant Prostate Cancer Be Detected with Multiparametric Magnetic Resonance Imaging? A Systematic Review of the Literature. *Eur Urol* 2015; **68**(6): 1045-53.
22. Dickinson L, Ahmed HU, Allen C, Barentsz JO, Carey B, Fütterer JJ et al. Scoring systems used for the interpretation and reporting of multiparametric MRI for prostate cancer detection, localization, and characterization: Could standardization lead to improved utilization of imaging within the diagnostic pathway? *J Magn Reson Imaging* 2013; **37**: 48–58.
23. Kirkham A, Haslam P, Keanie JY, McCafferty I, Padhani AR, Punwani S et al. Prostate MRI: Who, when, and how? Report from a UK consensus meeting. *Clin Radiol* 2013; **68**(10): 1016-23.
24. Rosenkrantz AB, Lim RP, Haghighi M, Somberg MB, Babb JS, Taneja SS. Comparison of interreader reproducibility of the prostate imaging reporting and data system and likert scales for evaluation of multiparametric prostate MRI. *AJR Am J Roentgenol* 2013; 201(4): W612-8

- 1
2
3 25. Bass EJ, Donaldson IA, Freeman A, Jameson C, Punwani S, Moore C et al.
4 Magnetic resonance imaging targeted transperineal prostate biopsy: a local
5 anaesthetic approach. *Prostate Cancer Prostate Dis.* 2017 [cited 2017 May
6 9]. Available from: <https://www.ncbi.nlm.nih.gov/pubmed/28485391> DOI:
7 10.1038/pcan.2017.13
8
9
10
11
12 26. Ahmed HU, Hu Y, Carter T, Arumainayagam N, Lecornet E, Freeman A et al.
13 Characterizing Clinically Significant Prostate Cancer Using Template Prostate
14 Mapping Biopsy. *J Urol* 2011; **186**(2): 458-464.
15
16
17
18 27. King CR, McNeal JE, Gill H, Presti J. Extended prostate biopsy scheme
19 improves reliability of Gleason grading for radiotherapy patients. *Int J Radiat*
20 *Oncol Biol Phys* 2004; **59**(2): 386–91.
21
22
23
24 28. Chen ME, Troncoso P, Johnston DA, Tang K, Babaian RJ. Optimization of
25 prostate biopsy strategy using computer based analysis. *J Urol.* 1997;
26 158:2168.
27
28
29
30 29. Levine MA, Ittman M, Melamed J, Lepor H. Two consecutive sets of
31 transrectal ultrasound guided sextant biopsies of the prostate for the
32 detection of prostate cancer. *J Urol* 1998; **159**: 471
33
34
35
36 30. Meng MV, Elkin EP, DuChane J, Carroll PR. Impact of increased number of
37 biopsies on the nature of prostate cancer identified. *J Urol* 2006; **176**: 63
38
39
40
41 31. Haas GP, Delongchamps NB, Jones RF, Chandan V, Serio AM, Vickers AJ et al.
42 Needle biopsies on autopsy prostates: sensitivity of cancer detection based
43 on true prevalence. *J Natl Cancer Inst* 2007; **99**: 1484.
44
45
46
47 32. Haas GP, Delongchamps N, Brawley OW, Wang CY, de la Roza G. The
48 worldwide epidemiology of prostate cancer: perspectives from autopsy
49 studies. *Can J Urol* 2008; **15**(1): 3866–71.
50
51
52
53 33. Ghafoori M, Velayati M, Aliyari Ghasabeh M, Shakiba M, Alavi M. Prostate
54 biopsy using transrectal ultrasonography; the optimal number of cores
55
56
57
58
59
60

- 1
2
3 regarding cancer detection rate and complications. *Iran J Radiol* 2015; 12:
4 e13257
5
6
7
8 34. Carignan A, Roussy JF, Lapointe V, Valiquette L, Sabbagh R, Pepin J. Increasing
9 risk of infectious complications after transrectal ultrasound-guided prostate
10 biopsies: time to reassess antimicrobial prophylaxis? *Eur Urol* 2012; 62:453–
11 459.
12
13
14
15 35. Pepdjonovic L, Tan GH, Huang S, Mann S, Frydenberg M, Moon D et al. Zero
16 hospital admissions for infection after 577 transperineal prostate biopsies
17 using single-dose cephazolin prophylaxis. *World J Urol* 2017; **35**(8):1199-1203
18
19
20
21 36. Loeb S, Vellekoop A, Ahmed HU, Catto J, Emberton M, Nam R et al.
22 Systematic review of complications of prostate biopsy. *Eur Urol* 2013; **64**(6):
23 876-92
24
25
26
27 37. Abd-Alazeez M, Kirkham A, Ahmed HU, Arya M, Anastasiadis E, Charman SC
28 et al. Performance of multiparametric MRI in men at risk of prostate cancer
29 before the first biopsy: a paired validating cohort study using template
30 prostate mapping biopsies as the reference standard. *Prostate Cancer*
31 *Prostatic Dis* 2014; **17**(1): 40-6.
32
33
34
35
36
37 38. Ahmed HU, Bosaily AS, Brown LC, Gabe R, Kaplan R, Parmar MK et al.
38 Diagnostic accuracy of multi-parametric MRI and TRUS biopsy in prostate
39 cancer (PROMIS): a paired validating confirmatory study. *Lancet* 2017.
40 25;389(10071): 815-822
41
42
43
44
45 39. Mottet N, Bellmunt J, Briers E, Bolla M, Cornford P, De Santis M et al. EAU –
46 ESTRO – SIOG Guidelines on Prostate Cancer. Available from:
47 [https://uroweb.org/wp-content/uploads/EAU-Guidelines-Prostate-Cancer-](https://uroweb.org/wp-content/uploads/EAU-Guidelines-Prostate-Cancer-2016.pdf)
48 [2016.pdf](https://uroweb.org/wp-content/uploads/EAU-Guidelines-Prostate-Cancer-2016.pdf). [Accessed 8th February 2018]
49
50
51
52
53 40. National Institute of Clinical Excellence. Prostate cancer: diagnosis and
54 management 2014. Available from
55
56
57
58
59
60

- 1
2
3 [https://www.nice.org.uk/guidance/cg175/chapter/1-](https://www.nice.org.uk/guidance/cg175/chapter/1-recommendations#assessment-2)
4 [recommendations#assessment-2](https://www.nice.org.uk/guidance/cg175/chapter/1-recommendations#assessment-2). [Accessed 8th February 2018]
5
6
7
8 41. Barentsz JO, Weinreib JC, Verma S, Thoeny HC, Tempny CM, Shtern F et al.
9 Synopsis of the PI-RADS v2 Guidelines for Multiparametric Prostate Magnetic
10 Resonance Imaging and Recommendations for Use. *Eur Urol* 2016; **69**(1): 41-
11 49
12
13
14
15 42. Valerio M, Donaldson, Emberton M, Ehdaie B, Hadaschik BA, Marks LS et al.
16 Detection of Clinically Significant Prostate Cancer Using Magnetic Resonance
17 Imaging-Ultrasound Fusion Targeted Biopsy: A Systematic Review. *Eur Urol*
18 2015; **68**(1): 8-19.
19
20
21
22
23 43. Moore CM, Robertson N, Arsonious N, Middleton T, Villers A, Klotz L et al.
24 Image-Guided Prostate Biopsy Using Magnetic Resonance Imaging-Derived
25 Targets: A Systematic Review. *Eur Urol* 2013; **63**(1): 125-140.
26
27
28
29 44. Filson CP, Natarajan S, Margolis DJ, Huang J, Lieu P, Dorey FJ et al: Prostate
30 cancer detection with magnetic resonance-ultrasound fusion biopsy: The role
31 of systematic and targeted biopsies. *Cancer* 2016; **122**: 884-892.
32
33
34
35 45. Cool DW, Zhang X, Romagnoli C, Izawa JI, Romano WM & Fenster A.
36 Evaluation of MRI-TRUS fusion versus cognitive registration accuracy for MRI-
37 targeted, TRUS-guided prostate biopsy. *AJR AM J Roentgenol* 2015; **204**(1):
38 83-91
39
40
41
42
43 46. Wegelin O, van Melick HH, Hooft L, Bosch JL, Reitsma HB, Barentsz JO et al.
44 Comparing Three Different Techniques for Magnetic Resonance Imaging-
45 targeted Prostate Biopsies: A Systematic Review of In-bore versus Magnetic
46 Resonance Imaging-transrectal Ultrasound fusion versus Cognitive
47 Registration. Is There a Preferred Technique? *Eur Urol* 2017; **71**(4): 517-531
48
49
50
51
52 47. Albertsen PC, Marks LS. MRI before Prostate Biopsy – Yes or No? *J Urol* 2013;
53 **190**: 1978-80
54
55
56
57
58
59
60

- 1
2
3 48. Cerantola Y, Dragomir A, Tanguay S, Bladou F, Aprikian A, Kassouf W. Cost-
4 effectiveness of multiparametric magnetic resonance imaging and targeted
5 biopsy in diagnosing prostate cancer. *Urol Oncol* 2016; **34**(3): 119e1-9
6
7
8
9 49. Faria R, Soares MO, Spackman E, Ahmed HU, Brown LC, Kaplan R et al.
10 Optimising the Diagnosis of Prostate Cancer in the Era of Multiparametric
11 Magnetic Resonance Imaging: A Cost-effectiveness Analysis Based on the
12 Prostate MR Imaging Study (PROMIS). *Eur Urol* 2018. **73**(1):23-30
13
14
15
16
17 50. NHS England. Waiting Times for Suspected and Diagnosed Cancer Patients:
18 2016/17 Annual Report. Available from:
19 [https://www.england.nhs.uk/statistics/wp-](https://www.england.nhs.uk/statistics/wp-content/uploads/sites/2/2017/06/Cancer-Waiting-Times-Annual-Report-201617-1.pdf)
20 [content/uploads/sites/2/2017/06/Cancer-Waiting-Times-Annual-Report-](https://www.england.nhs.uk/statistics/wp-content/uploads/sites/2/2017/06/Cancer-Waiting-Times-Annual-Report-201617-1.pdf)
21 [201617-1.pdf](https://www.england.nhs.uk/statistics/wp-content/uploads/sites/2/2017/06/Cancer-Waiting-Times-Annual-Report-201617-1.pdf) [Accessed 21st December 2017]
22
23
24
25
26 51. White S, Hricak H, Forstner R, Kurhanewicz J, Vigneron DB, Zaloudek CJ, et al.
27 Prostate cancer: effect of postbiopsy hemorrhage on interpretation of MR
28 images. *Radiology* 1995; **195**: 385–390
29
30
31
32
33
34

Figure and Table legends

35
36
37
38 **Figure 1:** The One-Stop mpMRI led, MRTB prostate cancer diagnostic pathway.

39
40
41
42 **Figure 2:** A pictorial prostate mpMRI diagrammatic report, as drawn by the
43 urologist.

44
45
46
47 **Figure 3:** The University College London ‘traffic light like’ system to define significant
48 prostate cancer.

49
50
51
52 **Table 1A:** Baseline demographics for the cohort.

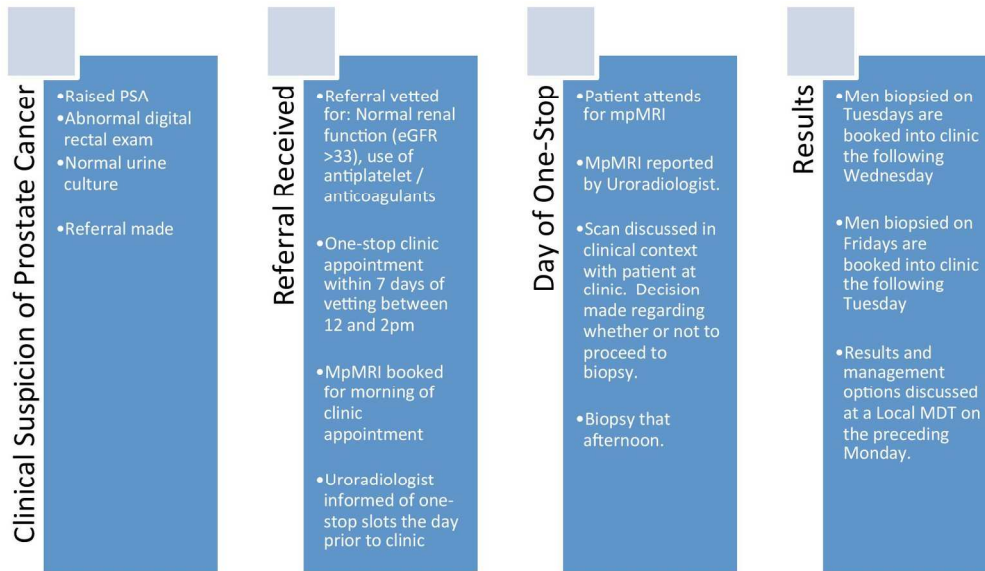
53
54
55
56 **Table 1B:** MpMRI outcomes.

57
58
59
60 **Table 1C:** Biopsy outcomes.

Table 1D: Diagnosis and treatment outcomes.

For peer review only

1
2
3
4
5
6
7
8
9
10
11
12
13
14
15
16
17
18
19
20
21
22
23
24
25
26
27
28
29
30
31
32
33
34
35
36
37
38
39
40
41
42
43
44
45
46
47
48
49
50
51
52
53
54
55
56
57
58
59
60

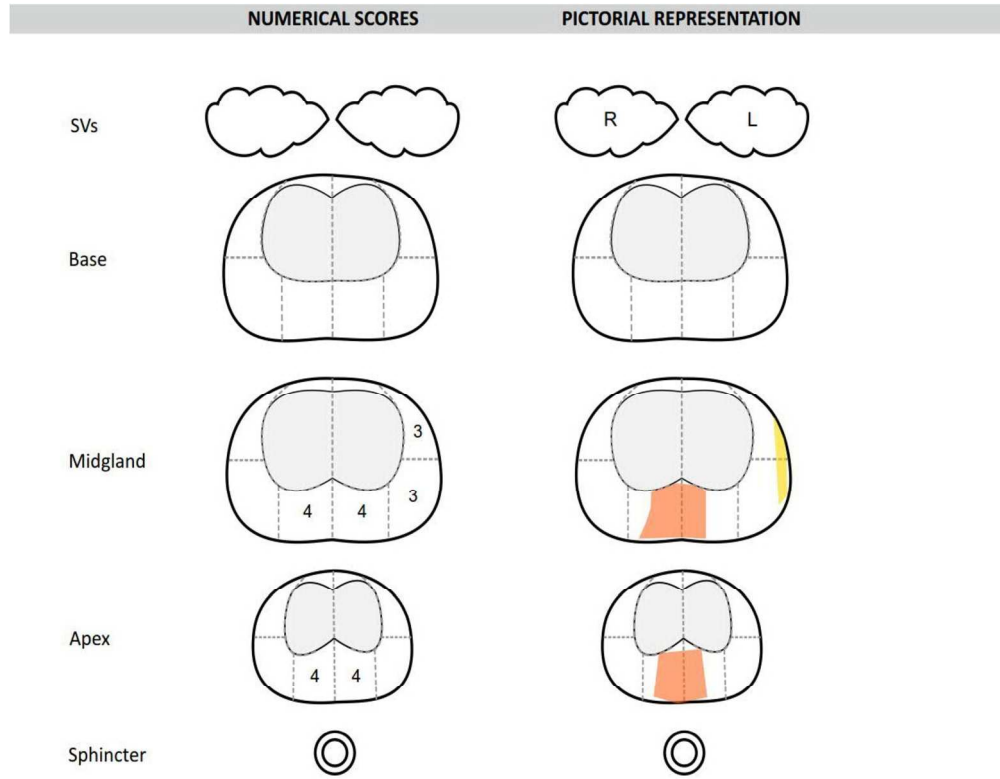


The One-Stop mpMRI led, MRTB prostate cancer diagnostic pathway.

168x97mm (300 x 300 DPI)

Review only

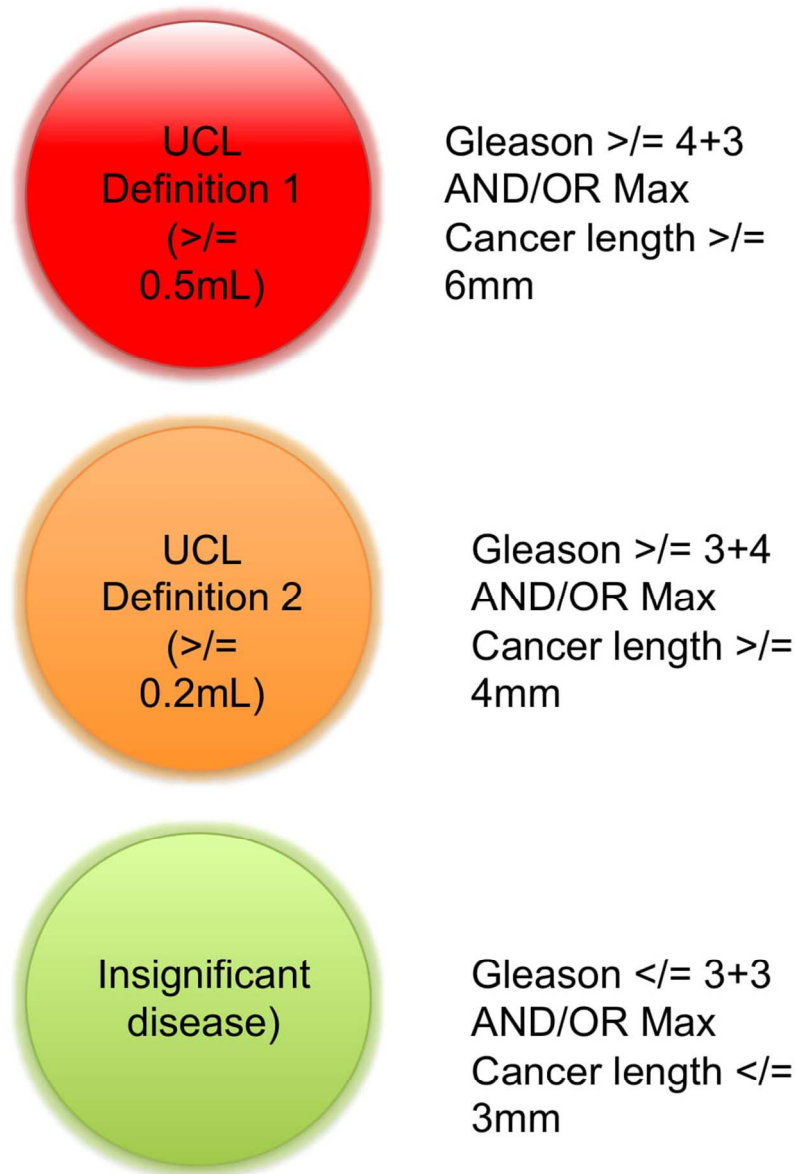
1
2
3
4
5
6
7
8
9
10
11
12
13
14
15
16
17
18
19
20
21
22
23
24
25
26
27
28
29
30
31
32
33
34
35
36
37
38
39
40
41
42
43
44
45
46
47
48
49
50
51
52
53
54
55
56
57
58
59
60



A pictorial prostate mpMRI diagrammatic report, as drawn by the urologist.

261x230mm (300 x 300 DPI)

1
2
3
4
5
6
7
8
9
10
11
12
13
14
15
16
17
18
19
20
21
22
23
24
25
26
27
28
29
30
31
32
33
34
35
36
37
38
39
40
41
42
43
44
45
46
47
48
49
50
51
52
53
54
55
56
57
58
59
60



The University College London 'traffic light like' system to define significant prostate cancer.

89x125mm (300 x 300 DPI)

1
2
3
4
5
6
7
8
9
10
11
12
13
14
15
16
17
18
19
20
21
22
23
24
25
26
27
28
29
30
31
32
33
34
35
36
37
38
39
40
41
42
43
44
45
46
47
48
49
50
51
52
53
54
55
56
57
58
59
60

BMJ Open

The Prostate Cancer Diagnostic Pathway: Is a One-Stop Cognitive Magnetic Resonance Imaging Targeted Biopsy Service A Realistic Goal in Everyday Practice? A pilot cohort in a Tertiary Referral Centre in the United Kingdom.

Journal:	<i>BMJ Open</i>
Manuscript ID	bmjopen-2018-024941.R1
Article Type:	Research
Date Submitted by the Author:	24-Aug-2018
Complete List of Authors:	Bass, Edward; Imperial College Healthcare NHS Trust, Imperial Urology Freeman, Alex; University College London Hospital, Department of Pathology Jameson, Charles; University College London Hospital, Department of Pathology Punwani, Shonit; University College London Medical School, Centre for Medical Imaging Moore, Caroline; University College London, Division of Surgery and Interventional Sciences Arya, Manit; University College London Hospital, Department of Urology Emberton, Mark; University College London, Division of Surgery and Interventional Sciences; University College London Hospital, Department of Urology Ahmed, Hashim; Imperial College Healthcare NHS Trust, Imperial Urology
Primary Subject Heading:	Urology
Secondary Subject Heading:	Health services research
Keywords:	Protocols & guidelines < HEALTH SERVICES ADMINISTRATION & MANAGEMENT, Prostate disease < UROLOGY, Magnetic resonance imaging < RADIOLOGY & IMAGING, Adult urology < UROLOGY

SCHOLARONE™
Manuscripts

1
2
3
4
5
6
7
8
9
10
11
12
13
14
15
16
17
18
19
20
21
22
23
24
25
26
27
28
29
30
31
32
33
34
35
36
37
38
39
40
41
42
43
44
45
46
47
48
49
50
51
52
53
54
55
56
57
58
59
60

The Prostate Cancer Diagnostic Pathway: Is a One-Stop Cognitive Magnetic Resonance Imaging Targeted Biopsy Service A Realistic Goal in Everyday Practice? A pilot cohort in a Tertiary Referral Centre in the United Kingdom.

Edward J Bass MBChB [1,2], Alex Freeman FRCPATH [5], Charles Jameson FRCPATH [5], Shonit Punwani FRCR [4], Caroline Moore FRCS (Urol) [1,2], Mani Arya FRCS (Urol) [1,2,6], Mark Emberton FRCS (Urol) [1,2], Hashim U. Ahmed FRCS (Urol) [7,8]

Affiliations

1. Division of Surgery and Interventional Science, University College London, London, UK
2. Department of Urology, University College London Hospitals NHS Foundation Trust, London, UK
3. Centre for Medical Imaging, Division of Medicine, University College London, London, UK
4. Department of Radiology, University College London Hospitals NHS Foundation Trust, London, UK
5. Department of Histopathology, University College London Hospitals NHS Foundation Trust, London, UK
6. Department of Urology, Princess Alexandra Hospital NHS Trust, Harlow, UK
7. Division of Surgery, Department of Surgery and Cancer, Faculty of Medicine, Imperial College London, UK
8. Imperial Urology, Charing Cross Hospital, Imperial College Healthcare NHS Trust, London, UK

Address for correspondence

Mr Edward Bass
Imperial Urology
Charing Cross Hospital
Imperial College Healthcare NHS Trust
Fulham Palace Road
London
W6 8RF

Email

Edward.bass@nhs.net

Key words

Transperineal prostate biopsy
Prostate cancer diagnostic pathway
Local Anaesthetic
Targeted prostate biopsy

Abstract word count

286

Manuscript main word count

3356

Abstract

Objectives

To evaluate the feasibility of a novel multiparametric magnetic resonance imaging (mpMRI) and cognitive fusion transperineal targeted biopsy led prostate cancer (PCa) diagnostic service with regard to cancer detection and reducing time to diagnosis and treatment.

Design

Consecutive men being investigated for possible prostate cancer under the United Kingdom two week wait guidelines.

Setting

Tertiary referral centre for prostate cancer in the United Kingdom.

Participants

Men referred with a raised prostate specific antigen (PSA) or abnormal digital rectal examination (DRE) between 02/2015 and 03/2016 under the United Kingdom two week rule guideline.

Interventions

An mpMRI was performed prior to patients attending clinic, on the same day. If required, MRTB was offered. Results were available within 48 hours and discussed at a specialist multidisciplinary team (MDT) meeting. Patients returned for counselling within 7 days

Primary and Secondary Outcome Measures

Outcome measures in this regard included the time to diagnosis and treatment of patients referred with a suspicion of prostate cancer. Quality control outcome measures included clinically significant and total cancer detection rates.

Results

1
2
3 112 men were referred to the service. 111 (99.1%) underwent mpMRI. Median PSA
4 was 9.4ng/mL [IQR 5.6-21.0]. 87 patients had a target on mpMRI with 25 scoring
5 Likert 3/5 for likelihood of disease, 26 4/5 and 36 5/5.
6
7

8
9 57 (51%) patients received a local anaesthetic, MRTB. Cancer was detected in 45
10 (79%). 43 (96%) had University College London (UCL) definition 2 disease or greater.
11
12 The times to diagnosis and treatment were a median of 8 and 20 days respectively.
13

14 15 **Conclusions**

16
17 This approach greatly reduces the time to diagnosis and treatment. Detection rates
18 of significant cancer are high. Similar services may be valuable to patients with a
19 potential diagnosis of PCa.
20
21
22
23
24
25
26
27

28 29 **Strengths and limitations of this study**

- 30
31 • First prospective study demonstrating the clinical feasibility of a 'one stop',
32 rapid diagnostic prostate cancer pathway, using both multiparametric
33 magnetic resonance imaging and transperineal targeted biopsy.
34
- 35
36 • Inclusion criteria reflecting 'real world' practice in the United Kingdom.
37
- 38
39 • This study incorporates a standardised multiparametric MRI acquisition and a
40 validated system for defining clinically significant prostate cancer.
41
- 42
43 • Cognitive targeted biopsy performed only, rather than mpMRI / ultrasound
44 fusion.
45
- 46
47 • Transperineal, rather than transrectal approach offers minimal septic
48 complications post biopsy.
49
50
51
52
53
54
55
56
57
58
59
60

Introduction

Accurate risk stratification for men presenting with localised prostate cancer is vitally important. In its absence, patient centred management cannot be offered. Men with low-risk disease can be safely managed with active surveillance, whereas men with a good life expectancy and intermediate to high-risk disease are likely to benefit from interventional treatment[1-2]. Currently, standard practice uses prostate-specific antigen (PSA) value, digital rectal examination (DRE) and transrectal ultrasound guided biopsy (TRUSGB). However, TRUSGB is inherently random. The tumour cannot be visualised with certainty, and thus leads to overdiagnosis of insignificant disease in up to 50% of men[3], and missing significant disease in 18% of men, especially if cancer is located in anterior or apical regions of the prostate[4]. This creates difficulty for urologists and adds anxiety to patients[5] who have to undergo a repetitive cascade of diagnostic tests, which inevitably has cost implications for healthcare providers.

Transperineal mapping or zonal biopsies (TPM) of the prostate offer a diagnostic alternative to TRUS biopsy with demonstrable diagnostic success. However, the burden on patients is high. Firstly, the extensive biopsies demand general anaesthesia. Secondly, the rates of urinary retention following the procedure are high, making postoperative catheterization commonplace. Thirdly, the large number of cores taken requires many hours of labour to assess. Thus, a patient may have to wait significantly longer for a result, adding to their anxiety. This may also delay necessary treatment. Whether this results in adverse outcomes is not known. However, all of these established difficulties do confer added costs. Indeed, if every patient undergoing TRUSGB instead underwent a TPM, the cost of such a move would likely be exceedingly high. Therefore, the challenge presents itself as biopsy offering superior clinically significant detection rates to the existing standard, whilst not conferring an added cost.

Multiparametric magnetic resonance imaging (mpMRI) of the prostate has proved a useful tool in the diagnosis and risk stratification of prostate cancer. MpMRI has demonstrated its ability to detect significant cancers, whilst not detecting those

1
2
3 which are insignificant[4]. Suspicious areas on mpMRI can be targeted with
4 subsequent transperineal biopsy (MRTB). MRTB has demonstrated greater sampling
5 efficiency and accuracy when compared with standard TRUS-guided protocols[6-8],
6 and has demonstrated accuracy when compared to the reference standard of radical
7 prostatectomy (RP)[9]. This allows for a more accurate assessment of Gleason
8 grade, and therefore an improved risk stratification and treatment plan at
9 diagnosis[10]. Furthermore, the efficiency advantage, i.e. taking fewer cores at
10 biopsy, confers significant benefits in cost, patient tolerability and post biopsy sepsis
11 rates.
12

13
14
15 Three methods of transperineal MRTB currently exist. First and most common is
16 'cognitive targeting'. This approach requires the urologist to review the mpMRI
17 images and aim the needle toward the corresponding area on ultrasound (US)
18 imaging[11]. Alternatively, the reporting urologist draws a diagrammatic
19 representation of the gland and any suspicious area contained within, which guides
20 the urologist to potential cancer. Second, 'in-bore MRTB' is performed whilst the
21 patient is in the MRI scanner, allowing for real time targeting of suspicious areas
22 with MRI compatible biopsy equipment. Third, 'fusion targeting' uses specifically
23 designed software to allow combination of the mpMRI images with real time US
24 imaging[4]. The latter two methods have implications in terms of equipment
25 availability and cost, and as of yet the question of superiority of any one over
26 another remains elusive[4].
27
28
29
30
31
32
33
34
35
36
37
38
39
40

41 Currently, prostate cancer diagnostic pathways remain built around TRUSGB.
42 MpMRI is more commonly being used prior to TRUSGB. However, the use of an
43 mpMRI and MRTB pathway remains a rarity despite the potential advantages of such
44 an approach and the novel approach of both diagnostic interventions in one day
45 exceptionally so. The reasons for this are multiple and commonly relate to the
46 techniques being in their relative infancy. The lack of standardised mpMRI
47 reporting[12], a learning curve for operators[13], mpMRI availability and cost[14]
48 and concern regarding missed diagnosis from not sampling the whole gland have all
49 been cited as reasons not to accept widespread adoption. Despite this, MRI-guided
50 targeted biopsy pathways have been utilised before, albeit via the transrectal rather
51
52
53
54
55
56
57
58
59
60

1
2
3 than the transperineal route[15-17]. The recent findings of the PRECISION [18] trial
4 has clearly addressed concerns in regard to superiority of an MRI-targeted biopsy
5 approach over systematic TRUS biopsy, demonstrating superiority in clinically
6 significant cancer detection rate and a reduction in the detection of insignificant
7 disease.
8
9

10
11
12 Thus, the objective of this pilot study was primarily to determine the suitability and
13 feasibility of a 'One-Stop', transperineal MRI-targeted biopsy pathway for prostate
14 cancer in 'real-world' clinical practice. Outcome measures in this regard included
15 the time to diagnosis and treatment of patients referred with a suspicion of prostate
16 cancer. Quality control outcome measures included clinically significant and total
17 cancer detection rates.
18
19
20
21
22
23
24
25

26 **Patients and Methods**

27
28 This prospective study analyses the clinical and service outcomes of an mpMRI and
29 MRTB led prostate cancer diagnostic pathway (*figure 1*) from 02/2015 to 03/2016.
30 Inclusion criteria were men presenting with a biochemical or clinical suspicion of
31 prostate cancer under the United Kingdom two week wait program and undergoing
32 mpMRI and if necessary subsequent cognitive targeted prostate biopsy. Patients
33 without negative urine cultures or with estimated glomerular filtration rates of <30
34 micromol/L were excluded. The patient was contacted on referral and an mpMRI
35 was arranged. This was reported before the patient attended clinic in the early
36 afternoon of the same day. If a targetable lesion was identified (Likert ≥ 4), a
37 transperineal-targeted biopsy was advised. If a target was rated as equivocal (Likert
38 =3), the discussion was more nuanced including risk factors for a subsequent biopsy
39 being positive such as a positive family history of prostate cancer, high PSA density
40 or concordant positive DRE findings. Further, in this group of men, those with diffuse
41 equivocal changes requiring a greater number of cores to be taken for a positive
42 result, the option of full template biopsies under general anaesthetic was discussed.
43 Results were available within 48 hours and were discussed at a specialist MDT.
44 Patients returned for counselling within seven days.
45
46
47
48
49
50
51
52
53
54
55
56
57
58
59
60

1
2
3 MpMRI acquisition was performed according to the European guidelines of Uro-
4 radiology previously described by the University College London (UCL)
5 group[12,19,20]. In summary this includes the use of a 1.5 or 3.0 Tesla MRI scanner
6 acquiring T2-weighted axial and coronal, axial diffusion weighted coefficient and
7 high *b*-value as well as T1 weighted dynamic contrast enhancement (intravenous
8 Gadolinium) images. Each scan was reported by an experienced uro-radiologist as
9 previously described [21,22] and a pictorial diagrammatic map drawn (*figure 2*).
10 Regions of interest (ROIs) were scored using a Likert-like scale of 1-5[22] using the
11 overall impression of the radiologist to characterise the level of suspicion for
12 prostate cancer. ROIs scoring 4 or 5 were thought 'likely' or 'highly likely' to contain
13 a malignant lesion, which was either ≥ 0.2 mL in volume and/or had high-grade
14 components within (Gleason $\geq 3+4$)[23]. ROIs 3 were rated as indeterminate for such
15 disease and this score of 3, or higher, was chosen as the threshold for a positive
16 mpMRI. Our choice of scoring system was based on the outcomes of the 2011
17 European Consensus Meeting[12] which met prior to the Prostate Imaging and Data
18 Reporting System (PIRADS) MP-MRI reporting consensus meeting[19] and has
19 demonstrated equivalency with the PIRADS system[24].

20
21
22
23
24
25
26
27
28
29
30
31
32
33 The procedure was performed as a day case under local anaesthesia and
34 antimicrobial prophylaxis in the lithotomy position, by either a consultant urologist
35 or urology clinical fellow as previously described[25]. This biopsy technique has
36 demonstrated a median procedure length of 30 minutes and good patient toleration,
37 with median visual analogue pain scores of 1.0[26].

38
39
40
41
42 Data was collected on a case report form compliant with the Standards of Reporting
43 for MRI-targeted Biopsy Studies (START) of the prostate[11]. Included data were
44 patients demographics, indications for biopsy, PSA value, prostate volume, number
45 of targets per patient, and Likert score per target[11]. Additionally, for each biopsy
46 collected the total number of cores taken, biopsy density, number of positive cores,
47 maximum and overall Gleason scores and the maximum cancer core length (MCCL).
48 Biopsy efficiency was calculated by the number of cores demonstrating clinically
49 significant disease divided by the number of cores taken. For the purpose of this
50 study, clinically significant disease was defined using the University College London
51
52
53
54
55
56
57
58
59
60

(UCL) classification for interpreting transperineal biopsy findings, which sets the significance threshold at Gleason score \geq to 3 + 4 and/or MCCL \geq 4 mm for definition 2 and \geq to 4 + 3 and/or MCCL \geq 6 mm for definition 1[26] (figure 3).

Finally, to assess the time to diagnosis and treatment as well as the treatments elected by men were determined by examination of the hospital trust's electronic data system.

Patient and Public Involvement

Participants were not involved in the design of the study. However, conclusions gleaned from the study are to be disseminated amongst patients newly referred to the service.

Results

Table 1

A. Patient Demographics		
Men included		112
Median Age (years)		68 [IQR 62-78]
Median PSA (ng/mL)		9.4 (IQR 5.6 - 21.0)
B. MpMRI Outcomes		
	n	%
Men undertaking mpMRI	111	99%
Median Prostate Volume (mL)	50 (IQR 35 - 78)	
Positive mpMRI (Men)	87	78%
Negative mpMRI (Men)	24	22%
Total ROIs	162	
1 ROIs / man	39	35%
2 ROIs / man	25	23%
3 ROIs / man	22	20%
4 ROIs / man	1	1%
Likert score per man		
Likert 3	25	23%
Likert 4	26	23%
Likert 5	36	32%
Total ROIs	162	

Median ROI volume (mL)	0.5 (IQR 0.2 - 1.0)			
<i>Likert score per lesion</i>				
Likert 3	71	44%		
Likert 4	49	30%		
Likert 5	42	26%		
C. Biopsy Outcomes				
	n	%		
Men undertaking biopsy	57	51%		
Median cores per patient	9 (IQR 5 - 12)			
Total cores	514			
Cores positive (UCL 2)	241	47%		
Biopsy efficiency	47%			
Median cores per lesion	4 (IQR 4 - 5)			
Median biopsy density (cores / ROI mL)	10 (IQR 3.5 - 20)			
Cancer detection by man				
Any Cancer	45	79%		
UCL 2	43	75%		
UCL 1	34	60%		
Gleason $\geq 3+4$	43	75%		
Gleason $\geq 4+3$	23	40%		
Median MCCL (mm)	7 (IQR 3 - 10)			
Cancer detection by lesion				
		Any cancer	UCL 2	UCL 1
Likert 3 (lesions biopsied)	40	13	10	4
Likert 4 (lesions biopsied)	38	24	19	15
Likert 5 (lesions biopsied)	35	35	35	28
D. Diagnosis and Treatment Outcomes				
Median time to diagnosis (days)	8 (IQR 5 - 12)			
Median time to treatment (days)	20 (IQR 8 - 40)			
<i>Treatment type (Post Biopsy)</i>				
	n	%		
Discharged	4	7%		
PSA Surveillance	6	11%		
Active Surveillance	5	9%		
Focal therapy	6	11%		
Robotic Prostatectomy	9	16%		
External Beam Radiotherapy	10	18%		
Brachytherapy	2	4%		
Androgen Deprivation Therapy	9	16%		
Chemotherapy	4	7%		
Antibiotics	1	2%		

Repeat biopsy | 1 2%

Patient demographics

In total, 112 consecutive biopsy naive men with a median age of 68 attended the prostate cancer one stop clinic between 02/2015 and 03/2016 (*Table 1A*). All but one man (99%) received an mpMRI scan prior to clinic. The patient in question had an MRI incompatible cardiac pacemaker.

MpMRI Outcomes

The median prostate volume was 50mL. Eighty-seven men (78%) had a positive mpMRI (Likert score ≥ 3) and 24 (22%) had a negative scan (Likert score ≤ 2) and did not go on to biopsy. Twenty-five men (29%) had an mpMRI scan with an overall Likert score of 3, 26 (30%) an overall score of 4 and 36 (41%) an overall Likert score of 5. There were 162 ROIs identified on mpMRI with a median volume of 0.5mL when measured on T2 MRI sequencing. Thirty-nine men (45%) had a single ROI on mpMRI, 25 men (29%) had two, 22 men (25%) had three and a single man (1%) had four. Seventy-one lesions (30%) were Likert 3, 49 (30%) at Likert 4 and 42 (26%) and Likert 5. After mpMRI, nine with negative mpMRIs (38%) were discharged for PSA surveillance in the community, 10 (42%) remained on PSA surveillance in secondary care, four (17%) underwent investigations for lower urinary tract symptoms and one (4%) underwent a full template biopsy under general anaesthetic (*Table 1B*).

Biopsy Outcomes

Fifty-seven men (51%) underwent a local anaesthetic MRTB as described following mpMRI (*Table 1C*). Fifteen (17%) men chose not to undergo biopsy under local anaesthetic and were listed for a biopsy under sedation. Thirteen men (15%) did not have a biopsy due to clinical reasons. Any cancer was detected in 45 (79%) of men. Of these, 43 (96%) satisfied the UCL 2 criteria for clinical significance and 34 (76%) satisfying the UCL 1 criteria. The median MCCL of positive biopsies was 7mm. The calculated biopsy efficiency for UCL 2 disease was 47%. The median number of cores

1
2
3 taken per ROI was 4, with a median calculated biopsy density of 10 cores/mL of ROI.
4 Of the 20 men who had more than one lesion on mpMRI and underwent biopsy, two
5 had a secondary lesion, which harboured either higher grade or volume disease. In
6 only one of these men was the secondary lesion a lower Likert score. Both such men
7 went on to radical prostatectomy.
8
9
10
11
12
13

14 **Diagnosis and Treatment Outcomes**

15
16
17 The median time to a man being told his diagnosis was eight days, and the median
18 time by which treatment had been started was 20 days, although in five cases this
19 time period was not clear (*Table 1D*). The treatment outcomes are shown in table
20 1D. Of note, 20 (18%) men were discharged after biopsy with 19 (17%) men starting
21 PSA surveillance. Forty-four (40%) went on to undergo treatment and nine (8%) men
22 underwent a further biopsy either due a perceived false negative or diffuse disease
23 requiring a biopsy under sedation or general anaesthetic. Eleven (10%) patients
24 underwent further assessment or treatment for benign disease.
25
26
27
28
29
30

31 **Discussion**

32
33
34 An optimal PCa diagnostic strategy should encapsulate maximal significant cancer
35 detection whilst avoiding insignificant disease or repeat biopsy. Furthermore, it
36 should convey enough information for urologists and patients to accurately devise a
37 treatment plan according to the risk of progression. However, as things stand, the
38 diagnostic pathway is still commonly led by TRUSGB, despite its accepted inaccuracy,
39 especially for disease located in the anterior or apical regions of the prostate[27]. In
40 particular the negative predictive value (NPV) of the originally described six core
41 TRUSGB is poor, with false negative rates of around 35%[28,29]. This inherent
42 disadvantage is somewhat mitigated by extending the biopsy to a 12 or even 24 core
43 technique, however increasing the number of cores past 12 leads to increased
44 numbers of insignificant cancers being detected[30,31] which is present in 40% of
45 men over the age of 50[32]. These cancers are rarely affect life expectancy or its
46 quality in any meaningful way and revealing them simply adds unnecessary burdens
47
48
49
50
51
52
53
54
55
56
57
58
59
60

1
2
3 to patients. Furthermore, increasing the number of cores may increase incidence of
4 post TRUSGB sepsis[33] and with the incidence already on the rise alongside
5 increasing prevalence of colonisation with resistant organisms such strategies pose
6 an increasing potential for harm[34] for which our clinical options are worryingly
7 limited. As a result, transperineal zonal or mapping biopsies (TPM) have become
8 more popular. In particular, one recent series reported a 0% readmission rate for
9 infective complications after targeted transperineal biopsy[35], in comparison to
10 rates of sepsis of up to 6.3% after TRUSGB[36]. However, there are significant
11 concerns regarding its cost, need for general anaesthetic, increased complications
12 and patient burden. Such concerns have justly prevented its wider use and certainly
13 a TPM led diagnostic pathway has not been seriously suggested.
14
15
16
17
18
19
20
21

22 However, the development and refinement of mpMRI demands that its use in
23 leading an approach to diagnosis must be contemplated. MpMRI has demonstrated
24 high levels of accuracy for the detection of clinically significant cancer when
25 compared to both TPM[37] and whole-mount prostatectomy specimens[9]. Indeed,
26 a systematic review by Fütterer et al found that mpMRI detected clinically significant
27 disease in up to 84% of men with a NPV of up to 98% where either TPM or
28 prostatectomy was used as the reference standard[20]. More recently the results of
29 the PROMIS trial demonstrate the sensitivity and negative predictive value of mpMRI
30 in detecting clinically significant disease as 93% and 89% respectively[38].
31 Furthermore, the PROMIS trial demonstrated that 27% of men could avoid a
32 biopsy[38]. Despite these findings, both the European Association of Urology
33 (EAU)[39] and National Institute of Clinical Excellence (NICE)[40] still do not
34 recommend mpMRI prior to an initial set of biopsies. In this study, leading with
35 mpMRI allowed 24 (21.6%) men to avoid a biopsy entirely. However, the majority
36 would remain on PSA surveillance due to the small – but understood - risk of a false
37 negative mpMRI. There is perhaps a concern that in less experienced centres
38 overcall images as PIRADS 3 is an issue that will expose men to unnecessary biopsies
39 and thus reducing the benefit of an image-guided pathway. However, as the PIRADS
40 v2[41] scoring system is increasingly adopted, with its ability to define a PIRADS 4
41 lesion over a 3 by utilisation of the second parameter (DCE and DWI for peripheral
42
43
44
45
46
47
48
49
50
51
52
53
54
55
56
57
58
59
60

1
2
3 zone and transition zone lesions respectively), alongside its more easily understood
4 and applicable design, should reduce such an effect going forward.
5
6

7
8 Clearly, there is enough evidence now to introduce an image-guided biopsy to the
9 PCa diagnostic pathway, bringing it in line with the current practice in other solid
10 organ malignancies. However, currently there is concern that targeted biopsies
11 alone risk missing areas of significant disease that appear normal on mpMRI. This
12 may be viewed as a limitation. However, our current approach to this cohort of men
13 was introduced after our paired analyses of mpMRI versus template biopsies
14 demonstrated that mpMRI cognitive biopsies had equivalent detection rates to zonal
15 mapping biopsies[37]. Furthermore, numerous centres have now reported
16 improved cancer detection rates of MRTB strategies when compared to systematic
17 approaches [42,43], as well as improved biopsy efficiency and reduced false negative
18 rates for significant cancer[8]. To underline this, another series of men who
19 underwent both fusion MRTB and systematic TPM showed a difference of clinically
20 significant cancer detection rates of 4% (28% for MRTB and 24% for systematic
21 biopsy), although combined biopsies outperformed each approach in isolation[44].
22 Naturally, such results have been reported by specialist centres and as such, concern
23 remains in regard to the level of operator dependency with targeted biopsy
24 techniques. However, authors have found no difference between cancer detection
25 rates with targeted techniques regardless of the experience of the operator, albeit
26 with TRUSGB[45]. Of course, advocating for a rapid uptake of such techniques in
27 centres with no prior experience would be optimistic. Instead, envisage a step-wise,
28 quality controlled uptake of transperineal approach biopsies, mpMRI reporting
29 before adopting targeted strategies.
30
31
32
33
34
35
36
37
38
39
40
41
42
43
44

45
46 As with mpMRI, MRTB is not a perfect test, both can miss significant disease.
47 However, this is an improvement on our current standard diagnostic test which is
48 demonstrably poor[27-30]. As recent studies have shown, in comparison to TRUSGB,
49 MRTB is more likely to detect disease once a suspicious area has been
50 identified[6,17]. Furthermore, the recently published PRECISION randomised
51 controlled trial clearly demonstrated the superior clinically significant cancer
52
53
54
55
56
57
58
59
60

1
2
3 detection rate of MRTB and a reduced insignificant cancer detection rate when
4 compared to systematic TRUS biopsy[18].
5

6
7 A potential limitation of the MRTB technique in this study is the use of 'cognitive
8 fusion' rather than US/mpMRI fusion or 'in-bore' targeting. However, no superiority
9 of one technique over another has been clearly demonstrated, whilst 'cognitive
10 fusion' is clearly a less costly option[46]. Another potential limitation of the targeted
11 biopsy strategy is the 'satisfaction of search' bias. Essentially, this means that after
12 the primary lesion is scored, less attention to detail is given to subsequent lesions,
13 which may therefore be undercalled or undersampled. However, in this series this
14 occurred twice, only once where the secondary lesion was attributed a lower score
15 than the primary, and in no cases did this change the proposed management.
16 Further, in the vast majority of centres where radical treatments – rather than focal
17 – remain the standard of care, there would likely be no change in the approach to
18 curative therapy, save for planning for prostatectomy in the case of nerve-sparing
19 procedures.
20
21

22
23 The cost of mpMRI has been cited as a reason for persisting with TRUSGB led
24 diagnostic pathways [47], using it instead for a second investigation in the case of a
25 negative biopsy in a patient in whom suspicion of cancer remains. Whilst mpMRI is
26 indeed useful in this scenario, recent cost effectiveness analyses have shown the
27 long term cost benefits of mpMRI led pathways when various outcomes are
28 accounted for[14,48,49] due to a reduction in overdiagnosis and higher detection
29 rates of clinically significant disease at primary biopsy. In particular, the cost-analysis
30 of the PROMIS trial cohort demonstrated that MpMRI first followed by two MRTBs
31 detects more cancer per pound spent than a TRUS first biopsy strategy[49].
32
33

34
35 A major advantage of our pathway is the low time to diagnosis and treatment. At a
36 median of 8 and 20 days respectively the time a patient waits is significantly below
37 the 31 and 62-day targets set by the United Kingdom National Health Service. The
38 meeting of these targets is a persistent challenge nationally[50]. Moreover,
39 performing an mpMRI prior to primary biopsy negates the risk of an initial false
40 negative biopsy significantly delaying a subsequent mpMRI due to post biopsy
41
42
43
44
45
46
47
48
49
50
51
52
53
54
55
56
57
58
59
60

1
2
3 haemorrhage within the prostate. This makes it difficult to localise cancer or
4 accurately determine its size or border[51]. In such circumstances, the delay in
5 diagnosis can be up to eight weeks.
6
7

8 9 **Conclusions**

10
11 This novel pathway offers an alternative to standard prostate cancer diagnostic
12 services. Attendance and cancer detection rates are high. The use of an mpMRI led
13 pathway allows for a significant proportion of men to avoid a biopsy and for those
14 who do, the time to diagnosis and definitive treatment is kept particularly low. The
15 integration of both mpMRI and MRTB in the prostate cancer diagnostic pathway has
16 shown cost-effectiveness in the long-term. This is especially true where rapid
17 diagnostics are mandated or desirable. Furthermore, today, where septic
18 complications are of grave concern, the transperineal route is particularly
19 advantageous. This pilot study demonstrates, that similar services can be provided in
20 appropriate centres and may be valuable to patients with a potential diagnosis of
21 prostate cancer.
22
23
24
25
26
27
28
29
30
31
32

33 **References**

- 34
35
36 1. Wilt TJ, Brawer MK, Jones KM, Barry MJ, Aronson WJ, Fox S, et al. Radical
37 prostatectomy versus observation for localized prostate cancer. *N Engl J Med*
38 2012; 367: 203–13.
39
40
41 2. Klotz L, Vesprini D, Sethukavalan P, Jethava V, Zhang L, Jain S, et al. Long-term
42 follow-up of a large active surveillance cohort of patients with prostate
43 cancer. *J Clin Oncol* 2015; 33: 272–7.
44
45
46 3. Loeb S, Bjurlin MA, Nicholson J, Tammela TL, Penson DF, Carter HB et al.
47 Overdiagnosis and overtreatment of prostate cancer. *Eur Urol* 2014; 65: 1046
48
49
50 4. Puech P, Rouviere O, Renard-Penna R, Villers A, Devos P, Colombel M et al.
51 Prostate cancer diagnosis: multiparametric MR-targeted biopsy with
52 cognitive and transrectal US-MR fusion guidance versus systematic biopsy—
53
54
55
56
57
58
59
60

- 1
2
3 prospective multicenter study. *Radiology* 2013; 268: 461
4
5
6 5. Brocken P, Prins JB, Dekhuijzen PN & van der Heijden HF. The faster the
7 better?-A systematic review on distress in the diagnostic phase of suspected
8 cancer, and the influence of rapid diagnostic pathways. *Psychooncology*
9 2012; **21**(1): 1-10
10
11
12
13 6. Moore CM, Robertson NL, Arsanious N, Middleton T, Villers A, Klotz L, et al.
14 Image-guided prostate biopsy using magnetic resonance imaging-derived
15 targets: a systematic review. *Eur Urol* 2013; 63: 125–40.
16
17
18
19 7. Siddiqui MM, Rais-Bahrami S, Turkbey B, George AK, Rothwax J, Shakir N, et
20 al. Comparison of MR/ultrasound fusion-guided biopsy with ultrasound-
21 guided biopsy for the diagnosis of prostate cancer. *J Am Med Assoc* 2015;
22 313: 390–7.
23
24
25
26
27 8. Schoots IG, Roobol MJ, Nieboer D, Bangma CH, Steyerberg EW, Hunink MG.
28 Magnetic resonance imaging-targeted biopsy may enhance the diagnostic
29 accuracy of significant prostate cancer detection compared to standard
30 transrectal ultrasound-guided biopsy: a systematic review and meta-analysis.
31 *Eur Urol* 2015; 68(3): 438-50
32
33
34
35
36
37 9. Puech P, Potiron E, Lemaitre L, Leroy X, Haber GP, Crouzet S et al. Dynamic
38 contrast-enhanced-magnetic resonance imaging evaluation of intraprostatic
39 cancer: correlation with radical prostatectomy specimens. *Urology* 2009; 74:
40 1094
41
42
43
44
45 10. Hambrock T, Hoeks C, Hulsbergen-van de Kaa C, Scheenen T, Fütterer J,
46 Bouwense S et al. Prospective assessment of prostate cancer aggressiveness
47 using 3-T diffusion-weighted magnetic resonance imaging-guided biopsies
48 versus a systematic 10-core transrectal ultrasound prostate biopsy cohort.
49 *Eur Urol* 2012; 61:177
50
51
52
53
54 11. Moore CM, Kasivisvanathan V, Eggener S, Emberton M, Fütterer JJ, Gill IS et
55 al. Standards of reporting for MRI-targeting biopsy studies (START) of the
56
57
58
59
60

- 1
2
3 prostate: recommendations from an International Working Group. *Eur Urol*
4 2013; 63: 544
5
6
7
8 12. Dickinson L, Ahmed HU, Allen C, Barentsz JO, Carey B, Fütterer JJ et al.
9 Magnetic resonance imaging for the detection, localization, and
10 characterization of prostate cancer: recommendations from a European
11 consensus meeting. *Eur Urol* 2011; 59: 7477
12
13
14
15 13. Gaziev G, Wadhwa K, Barrett T, Koo BC, Gallagher FA, Serrao E et al. Defining
16 the learning curve for multiparametric magnetic resonance imaging (MRI) of
17 the prostate using MRI-transrectal ultrasonography (TRUS) fusion-guided
18 transperineal prostate biopsies as a validation tool. *BJU Int* 2016; 117: 80-86
19
20
21
22
23 14. De Rooij M, Crienen S, Witjes JA, Barentsz JO, Rovers MM, Grutters JP. Cost-
24 effectiveness of magnetic resonance (MR) imaging and MR-guided targeted
25 biopsy versus systematic transrectal ultrasound-guided biopsy in diagnosing
26 prostate cancer: a modeling study from a health care perspective. *Eur Urol*
27 2014; 66: 430-436
28
29
30
31
32 15. Venderink W, van Luijelaar A, Bomers JG, van der Leest M, Hulsbergen-van
33 de Kaa C, Barentsz JO et al. Results of Targeted Biopsy in Men with Magnetic
34 Resonance Imaging Lesions Classified Equivocal, Likely or Highly Likely to Be
35 Clinically Significant Prostate Cancer. *Eur Urol* 2017 [cited 2018 Feb 9].
36 Available from: <https://www.ncbi.nlm.nih.gov/pubmed/28258784>
37
38
39
40
41
42 16. Nassiri N, Natarajan S, Margolis DJ & Marks LS. Targeted Prostate Biopsy:
43 Lessons Learned Midst the Evolution of a Disruptive Technology. *Urology*
44 2015; **86**(3): 432-438
45
46
47
48 17. Pokorny MR, de Rooij M, Duncan E, Schroder FH, Parkinson R, Barentsz JO et
49 al. Prospective study of diagnostic accuracy comparing prostate cancer
50 detection by transrectal ultrasound-guided biopsy versus magnetic resonance
51 (MR) imaging with subsequent MR-guided biopsy in men without previous
52 prostate biopsies. *Eur Urol* 2013; **66**: 22
53
54
55
56
57
58
59
60

- 1
2
3 18. Kasivisvanathan V, Ranniko AS, Borghi M, Panebianco V, Mynderse LA,
4 Vaarala MH. MRI-Targeted of Standard Biopsy for Prostate-Cancer Diagnosis.
5 *N Engl J Med* 2018. 378(19): 1767-1777.
6
7
8
9 19. Barentsz JO, Richenberg J, Clements R, Choyke P, Verma S, Villeirs S et al.
10 ESUR prostate MR guidelines 2012. *Eur Radiol* 2012; **22**(4): 746-57
11
12
13 20. Kasivisvanathan V, Dufour R, Moore CM, Ahmed HU, Abd-Alazeez M,
14 Charman SC, et al. Transperineal magnetic resonance image targeted
15 prostate biopsy versus transperineal template prostate biopsy in the
16 detection of clinically significant prostate cancer. *J Urol* 2013; 189:860–6.
17
18
19
20
21 21. Fütterer JJ, Briganti A, De Visschere P, Emberton M, Giannarini G, Kirkham A
22 et al. Can Clinically Significant Prostate Cancer Be Detected with
23 Multiparametric Magnetic Resonance Imaging? A Systematic Review of the
24 Literature. *Eur Urol* 2015; **68**(6): 1045-53.
25
26
27
28
29 22. Dickinson L, Ahmed HU, Allen C, Barentsz JO, Carey B, Fütterer JJ et al.
30 Scoring systems used for the interpretation and reporting of multiparametric
31 MRI for prostate cancer detection, localization, and characterization: Could
32 standardization lead to improved utilization of imaging within the diagnostic
33 pathway? *J Magn Reson Imaging* 2013; **37**: 48–58.
34
35
36
37
38 23. Kirkham A, Haslam P, Keanie JY, McCafferty I, Padhani AR, Punwani S et al.
39 Prostate MRI: Who, when, and how? Report from a UK consensus meeting.
40 *Clin Radiol* 2013; **68**(10): 1016-23.
41
42
43
44
45 24. Rosenkrantz AB, Lim RP, Haghghi M, Somberg MB, Babb JS, Taneja SS.
46 Comparison of interreader reproducibility of the prostate imaging reporting
47 and data system and likert scales for evaluation of multiparametric prostate
48 MRI. *AJR Am J Roentgenol* 2013; 201(4): W612-8
49
50
51
52 25. Bass EJ, Donaldson IA, Freeman A, Jameson C, Punwani S, Moore C et al.
53 Magnetic resonance imaging targeted transperineal prostate biopsy: a local
54 anaesthetic approach. *Prostate Cancer Prostate Dis*. 2017 [cited 2017 May
55
56
57
58
59
60

- 9]. Available from: <https://www.ncbi.nlm.nih.gov/pubmed/28485391> DOI: 10.1038/pcan.2017.13
26. Ahmed HU, Hu Y, Carter T, Arumainayagam N, Lecornet E, Freeman A et al. Characterizing Clinically Significant Prostate Cancer Using Template Prostate Mapping Biopsy. *J Urol* 2011; **186**(2): 458-464.
27. King CR, McNeal JE, Gill H, Presti J. Extended prostate biopsy scheme improves reliability of Gleason grading for radiotherapy patients. *Int J Radiat Oncol Biol Phys* 2004; **59**(2): 386–91.
28. Chen ME, Troncoso P, Johnston DA, Tang K, Babaian RJ. Optimization of prostate biopsy strategy using computer based analysis. *J Urol*. 1997; 158:2168.
29. Levine MA, Ittman M, Melamed J, Lepor H. Two consecutive sets of transrectal ultrasound guided sextant biopsies of the prostate for the detection of prostate cancer. *J Urol* 1998; **159**: 471
30. Meng MV, Elkin EP, DuChane J, Carroll PR. Impact of increased number of biopsies on the nature of prostate cancer identified. *J Urol* 2006; **176**: 63
31. Haas GP, Delongchamps NB, Jones RF, Chandan V, Serio AM, Vickers AJ et al. Needle biopsies on autopsy prostates: sensitivity of cancer detection based on true prevalence. *J Natl Cancer Inst* 2007; **99**: 1484.
32. Haas GP, Delongchamps N, Brawley OW, Wang CY, de la Roza G. The worldwide epidemiology of prostate cancer: perspectives from autopsy studies. *Can J Urol* 2008; **15**(1): 3866–71.
33. Ghafoori M, Velayati M, Aliyari Ghasabeh M, Shakiba M, Alavi M. Prostate biopsy using transrectal ultrasonography; the optimal number of cores regarding cancer detection rate and complications. *Iran J Radiol* 2015; **12**: e13257

- 1
2
3 34. Carignan A, Roussy JF, Lapointe V, Valiquette L, Sabbagh R, Pepin J. Increasing
4 risk of infectious complications after transrectal ultrasound-guided prostate
5 biopsies: time to reassess antimicrobial prophylaxis? *Eur Urol* 2012; 62:453–
6 459.
7
8
9
10
11 35. Pepdjonovic L, Tan GH, Huang S, Mann S, Frydenberg M, Moon D et al. Zero
12 hospital admissions for infection after 577 transperineal prostate biopsies
13 using single-dose cephazolin prophylaxis. *World J Urol* 2017; **35**(8):1199-1203
14
15
16
17 36. Loeb S, Vellekoop A, Ahmed HU, Catto J, Emberton M, Nam R et al.
18 Systematic review of complications of prostate biopsy. *Eur Urol* 2013; **64**(6):
19 876-92
20
21
22
23 37. Abd-Alazeez M, Kirkham A, Ahmed HU, Arya M, Anastasiadis E, Charman SC
24 et al. Performance of multiparametric MRI in men at risk of prostate cancer
25 before the first biopsy: a paired validating cohort study using template
26 prostate mapping biopsies as the reference standard. *Prostate Cancer*
27 *Prostatic Dis* 2014; **17**(1): 40-6.
28
29
30
31
32
33 38. Ahmed HU, Bosaily AS, Brown LC, Gabe R, Kaplan R, Parmar MK et al.
34 Diagnostic accuracy of multi-parametric MRI and TRUS biopsy in prostate
35 cancer (PROMIS): a paired validating confirmatory study. *Lancet* 2017.
36 25;389(10071): 815-822
37
38
39
40 39. Mottet N, Bellmunt J, Briers E, Bolla M, Cornford P, De Santis M et al. EAU –
41 ESTRO – SIOG Guidelines on Prostate Cancer. Available from:
42 [https://uroweb.org/wp-content/uploads/EAU-Guidelines-Prostate-Cancer-](https://uroweb.org/wp-content/uploads/EAU-Guidelines-Prostate-Cancer-2016.pdf)
43 [2016.pdf](https://uroweb.org/wp-content/uploads/EAU-Guidelines-Prostate-Cancer-2016.pdf). [Accessed 8th February 2018]
44
45
46
47
48 40. National Institute of Clinical Excellence. Prostate cancer: diagnosis and
49 management 2014. Available from
50 [https://www.nice.org.uk/guidance/cg175/chapter/1-](https://www.nice.org.uk/guidance/cg175/chapter/1-recommendations#assessment-2)
51 [recommendations#assessment-2](https://www.nice.org.uk/guidance/cg175/chapter/1-recommendations#assessment-2). [Accessed 8th February 2018]
52
53
54
55
56
57
58
59
60

- 1
2
3 41. Barentsz JO, Weinreib JC, Verma S, Thoeny HC, Tempny CM, Shtern F et al.
4 Synopsis of the PI-RADS v2 Guidelines for Multiparametric Prostate Magnetic
5 Resonance Imaging and Recommendations for Use. *Eur Urol* 2016; **69**(1): 41-
6 49
7
8
9
10
11 42. Valerio M, Donaldson, Emberton M, Ehdaie B, Hadaschik BA, Marks LS et al.
12 Detection of Clinically Significant Prostate Cancer Using Magnetic Resonance
13 Imaging-Ultrasound Fusion Targeted Biopsy: A Systematic Review. *Eur Urol*
14 2015; **68**(1): 8-19.
15
16
17
18 43. Moore CM, Robertson N, Arsonious N, Middleton T, Villers A, Klotz L et al.
19 Image-Guided Prostate Biopsy Using Magnetic Resonance Imaging-Derived
20 Targets: A Systematic Review. *Eur Urol* 2013; **63**(1): 125-140.
21
22
23
24 44. Filson CP, Natarajan S, Margolis DJ, Huang J, Lieu P, Dorey FJ et al: Prostate
25 cancer detection with magnetic resonance-ultrasound fusion biopsy: The role
26 of systematic and targeted biopsies. *Cancer* 2016; **122**: 884-892.
27
28
29
30 45. Cool DW, Zhang X, Romagnoli C, Izawa JI, Romano WM & Fenster A.
31 Evaluation of MRI-TRUS fusion versus cognitive registration accuracy for MRI-
32 targeted, TRUS-guided prostate biopsy. *AJR AM J Roentgenol* 2015; **204**(1):
33 83-91
34
35
36
37 46. Wegelin O, van Melick HH, Hooft L, Bosch JL, Reitsma HB, Barentsz JO et al.
38 Comparing Three Different Techniques for Magnetic Resonance Imaging-
39 targeted Prostate Biopsies: A Systematic Review of In-bore versus Magnetic
40 Resonance Imaging-transrectal Ultrasound fusion versus Cognitive
41 Registration. Is There a Preferred Technique? *Eur Urol* 2017; **71**(4): 517-531
42
43
44
45 47. Albertsen PC, Marks LS. MRI before Prostate Biopsy – Yes or No? *J Urol* 2013;
46 **190**: 1978-80
47
48
49
50 48. Cerantola Y, Dragomir A, Tanguay S, Bladou F, Aprikian A, Kassouf W. Cost-
51 effectiveness of multiparametric magnetic resonance imaging and targeted
52 biopsy in diagnosing prostate cancer. *Urol Oncol* 2016; **34**(3): 119e1-9
53
54
55
56
57
58
59
60

- 1
2
3 49. Faria R, Soares MO, Spackman E, Ahmed HU, Brown LC, Kaplan R et al.
4 Optimising the Diagnosis of Prostate Cancer in the Era of Multiparametric
5 Magnetic Resonance Imaging: A Cost-effectiveness Analysis Based on the
6 Prostate MR Imaging Study (PROMIS). *Eur Urol* 2018. **73**(1):23-30
7
8
9
10
11 50. NHS England. Waiting Times for Suspected and Diagnosed Cancer Patients:
12 2016/17 Annual Report. Available from:
13 [https://www.england.nhs.uk/statistics/wp-](https://www.england.nhs.uk/statistics/wp-content/uploads/sites/2/2017/06/Cancer-Waiting-Times-Annual-Report-201617-1.pdf)
14 [content/uploads/sites/2/2017/06/Cancer-Waiting-Times-Annual-Report-](https://www.england.nhs.uk/statistics/wp-content/uploads/sites/2/2017/06/Cancer-Waiting-Times-Annual-Report-201617-1.pdf)
15 [201617-1.pdf](https://www.england.nhs.uk/statistics/wp-content/uploads/sites/2/2017/06/Cancer-Waiting-Times-Annual-Report-201617-1.pdf) [Accessed 21st December 2017]
16
17
18
19
20 51. White S, Hricak H, Forstner R, Kurhanewicz J, Vigneron DB, Zaloudek CJ, et al.
21 Prostate cancer: effect of postbiopsy hemorrhage on interpretation of MR
22 images. *Radiology* 1995; **195**: 385–390
23
24
25
26
27
28

29 **Figure and Table legends**

30
31 **Figure 1:** The One-Stop mpMRI led, MRTB prostate cancer diagnostic pathway.
32

33
34 **Figure 2:** A pictorial prostate mpMRI diagrammatic report, as drawn by the
35 urologist.
36

37
38 **Figure 3:** The University College London ‘traffic light like’ system to define significant
39 prostate cancer.
40

41
42 **Table 1A:** Baseline demographics for the cohort.
43

44
45 **Table 1B:** MpMRI outcomes.
46

47
48 **Table 1C:** Biopsy outcomes.
49

50
51 **Table 1D:** Diagnosis and treatment outcomes.
52
53
54
55
56
57
58
59
60

Footnotes

Contributorship statement

Edward J Bass drafted the manuscript and approved the final version.

Alex Freeman contributed to the conception of the work presented, revised the manuscript critically and approved the final version.

Charles Jameson contributed to the conception of the work presented and revised the manuscript critically and approved the final version.

Shonit Punwani contributed to the conception of the work presented and revised the manuscript critically and approved the final version.

Caroline Moore contributed to the conception of the work presented and revised the manuscript critically and approved the final version.

Manit Arya revised the manuscript critically and approved the final version.

Mark Emberton contributed to the conception of the work presented and revised the manuscript critically and approved the final version.

Hashim U. Ahmed contributed to the conception of the work presented and revised the manuscript critically and approved the final version.

All authors are accountable for all aspects of the work in terms of accuracy and integrity.

Competing Interests

Hashim Ahmed's research is supported by core funding from the United Kingdom's National Institute of Health Research (NIHR) Imperial Biomedical Research Centre. This paper is independent research funded by the National Institute for Health Research (NIHR) Imperial Biomedical Research Centre (BRC). The views expressed in this publication are those of the author(s) and not necessarily those of the NHS, the National Institute for Health Research or the Department of Health.

Ahmed currently receives funding from the Wellcome Trust, Prostate Cancer UK, Sonacare Inc., Trod Medical and Sophiris Biocorp for trials in prostate cancer. Ahmed is a paid medical consultant for Sophiris Biocorp for trials work.

Mark Emberton's research is supported by core funding from the United Kingdom's National Institute of Health Research (NIHR) UCLH/UCL Biomedical Research Centre. He was awarded NIHR Senior Investigator in 2015.

Emberton receives funding from NIHR-i4i, MRC, Sonacare Inc., Trod Medical, Cancer Vaccine Institute and Sophiris Biocorp for trials in prostate cancer. Emberton is a medical consultant to Sonacare Inc., Sophiris Biocorp, Steba Biotech, Exact Imaging and Profound Medical.

Moore receives funding from the National Institute for Health Research, The European Association of Urology Research Foundation, Prostate Cancer UK, Movember and the Cancer Vaccine Institute, for clinical prostate cancer research. She has received advisory board fees for Genomic Health.

Ahmed, Emberton, and Moore are all proctors for HIFU and are paid for training other surgeons in this procedure.

Emberton and Freeman have loan notes/stock options in Nuada Medical Ltd (UK).

Funding

This research received no specific grant from any funding in the public, commercial or not-for-profit sectors.

Data sharing statement

We declare there is no unpublished data from etc study.

Patient Consent

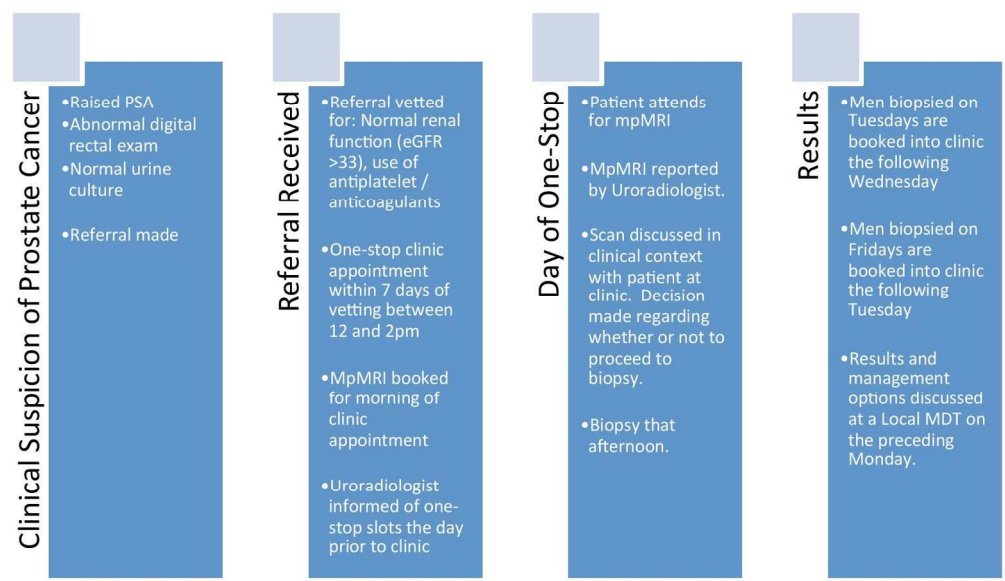
Consent was obtained prior to mpMRI and biopsy.

Ethics approval

Local ethical approval was attained through the Hospital Trust's audit committee

For peer review only

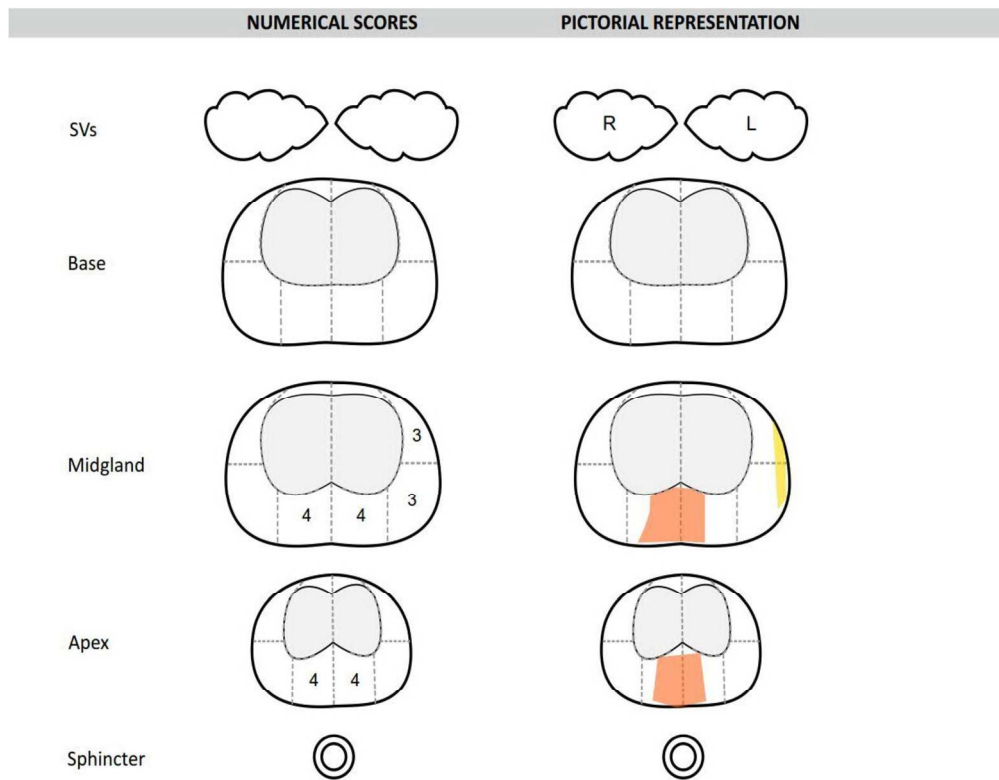
1
2
3
4
5
6
7
8
9
10
11
12
13
14
15
16
17
18
19
20
21
22
23
24
25
26
27
28
29
30
31
32
33
34
35
36
37
38
39
40
41
42
43
44
45
46
47
48
49
50
51
52
53
54
55
56
57
58
59
60



The One-Stop mpMRI led, MRTB prostate cancer diagnostic pathway.

168x97mm (300 x 300 DPI)

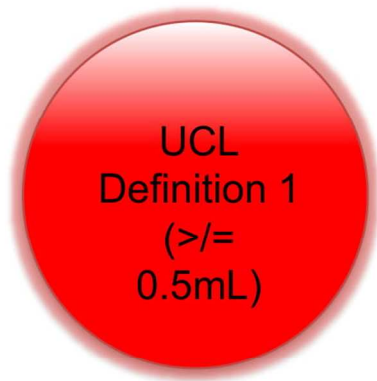
Review only



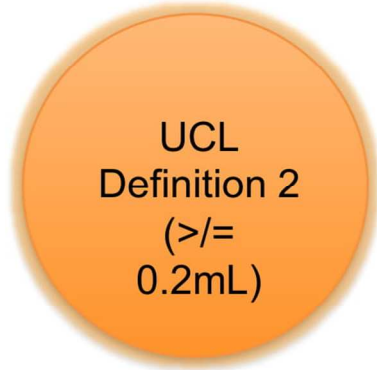
A pictorial prostate mpMRI diagrammatic report, as drawn by the urologist.

261x230mm (300 x 300 DPI)

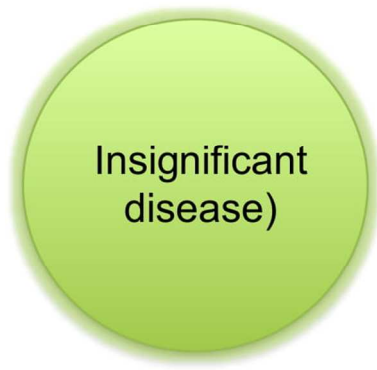1
2
3
4
5
6
7
8
9
10
11
12
13
14
15
16
17
18
19
20
21
22
23
24
25
26
27
28
29
30
31
32
33
34
35
36
37
38
39
40
41
42
43
44
45
46
47
48
49
50
51
52
53
54
55
56
57
58
59
60



Gleason $\geq 4+3$
AND/OR Max
Cancer length ≥ 6 mm



Gleason $\geq 3+4$
AND/OR Max
Cancer length ≥ 4 mm



Gleason $\leq 3+3$
AND/OR Max
Cancer length ≤ 3 mm

The University College London 'traffic light like' system to define significant prostate cancer.

89x125mm (300 x 300 DPI)

Item	Extension for pilot trials	Reported	Page	Line
Title	Identification of study as randomised pilot or feasibility trial	✓	7	6
Trial design	Description of pilot trial design (eg, parallel, cluster)	✓	7	14 - 29
Methods:				
Participants	Eligibility criteria for participants and the settings where the pilot trial was conducted	✓	7	17 - 20
Interventions	<i>Interventions intended for each group</i>	✓	8	1 - 22
Objective	Specific objectives of the pilot trial	✓	7	6 - 11
Outcome	Prespecified assessment or measurement to address the pilot trial objectives*	✓	7	10 - 11
Randomisation	<i>How participants were allocated to interventions</i>	N / A	N / A	N / A
Blinding (masking)	<i>Whether or not participants, care givers, and those assessing the objectives were blinded to group assignment</i>	N / A	N / A	N / A
Results:				
Numbers randomised	Number of participants screened and randomised to each group for the pilot trial objectives*	N / A	N / A	N / A
Recruitment				
Numbers analysed	Number of participants analysed in each group for the pilot objectives*	✓	11	2 - 3
Outcome	Results for the pilot objectives, including any expressions of uncertainty*	✓	12 & 13	19 - 26 & 1 - 15
Harms	<i>Important adverse events or side effects</i>	✗	✗	✗

1
2
3
4
5
6
7
8
9
10
11
12
13
14
15
16
17
18
19
20
21
22
23
24
25
26
27
28
29
30
31
32
33
34
35
36
37
38
39
40
41
42
43
44
45
46
47

Conclusions	General interpretation of the results of pilot trial and their implications for the future definitive trial	✓	15	23 - 26
Trial registration	Registration number for pilot trial and name of trial register	N/A	N/A	N/A
Funding	Source of funding for pilot trial	N/A	N/A	N/A

For peer review only