



Long-term clinical Results after Cataract Surgery with and without capsular Tension Ring in Patients with Retinitis Pigmentosa: A Retrospective Study

Journal:	<i>BMJ Open</i>
Manuscript ID:	bmjopen-2013-002616
Article Type:	Research
Date Submitted by the Author:	20-Jan-2013
Complete List of Authors:	Bayyoud, Tarek; Eberhard-Karls-University, University Eye Hospital Bartz-Schmidt, Karl; Eberhardt-Karls-University, University Eye Hospital Yoeruek, Efdal; Eberhardt-Karls-University, University Eye Hospital
Primary Subject Heading:	Ophthalmology
Secondary Subject Heading:	Genetics and genomics
Keywords:	Retinitis pigmentosa, Capsular Tension Ring, Capsular Contraction Syndrome, Phacoemulsification, Secondary cataract

SCHOLARONE™
Manuscripts

1
2
3
4
5
6
7
8
9
10
11
12
13
14
15
16
17
18
19
20
21
22
23
24
25
26
27
28
29
30
31
32
33
34
35
36
37
38
39
40
41
42
43
44
45
46
47
48
49
50
51
52
53
54
55
56
57
58
59
60

Long-term clinical Results after Cataract Surgery with and without capsular Tension Ring in Patients with Retinitis Pigmentosa: A Retrospective Study

Tarek Bayyoud, MD, Karl Ulrich Bartz- Schmidt, MD, Efdal Yoeruek, MD.

Department of Ophthalmology, Eberhard-Karls University Tuebingen, Germany.

Corresponding author:

Tarek Bayyoud, University Eye Hospital, Department of Ophthalmology, Eberhard-Karls University, Schleichstr. 12, 72076 Tuebingen, Germany; Phone+49-7071-2983728, Fax+49-7071-294674. tarek_bayyoud@gmx.de

T. Bayyoud, None; KU Bartz-Schmidt, None; E. Yoeruek, None.

Funding statement: This research received no specific grant from any funding agency in the public, commercial or not-for-profit sectors. The authors declare that they have no competing interests.

Contributorship statement: Contributors: Bayyoud acquisition of data, cleaned and analysed the data, wrote the statistical analysis plan, drafted and revised the paper and was involved in final approval. Yoeruek conceptualized the project, monitored data collection, drafted and revised the paper and was involved in final approval. Bartz-Schmidt contributed to conception, revised the draft paper and was involved in final approval.

Competing Interests: None

Data Sharing: No additional unpublished data shared.

Word count: 1547

1
2
3
4
5
6
7
8
9
10
11 **Article Summary:** *Long-term clinical Results after Cataract Surgery with and without*
12 *capsular Tension Ring in Patients with Retinitis Pigmentosa: A Retrospective Study*
13
14

15
16
17 Article Focus:

- 18
19
20
 - Long-term clinical outcomes after cataract surgery with and without capsular

21
22 tension ring in a group of retinitis pigmentosa patients
23
24

25 Key messages:

- 26
27
28
 - Both surgical approaches were of benefit to retinitis pigmentosa patients

29
30
 - Surgery with capsular tension ring implantation resulted in significantly fewer

31
32 long-term postoperative complications
33
34
 - These include secondary cataract and capsular contraction syndrome

35
36
37

38 Strength and limitations:

- 39
40
 - Relatively small sample size of this special subset of cataract patients

41
42
43
44
45
46
47
48
49
50
51
52
53
54
55
56
57
58
59
60

ABSTRACT

Objectives: To describe the long-term clinical outcomes after cataract surgery with and without capsular tension ring (CTR) in a group of retinitis pigmentosa (RP) patients

Design: Retrospective study

Setting: Tertiary referral center

Participants: 88 eyes (59 patients) with RP

Interventions: Cataract surgery was undertaken between 10/2002 and 05/2010

Primary and secondary outcome measures: Visual acuity, secondary cataract, capsular contraction syndrome (CCS), intraocular pressure, cystoid macular edema (CME), intraocular lens dislocation and endophthalmitis

Results: The mean age at surgery was about 55 years and the overall mean follow-up 32 months (range 3-97 months). The mean preoperative LogMAR BCVA in the whole group was 1.35 +/-0.84 (95 % CI: 1.17-1.53) and increased to 1.19 +/-0.90 (95 % CI: 1.0-1.38) (p-value = 0.0006). The mean preoperative and the mean postoperative LogMAR BCVA in the non-CTR group (group one) improved from 1.17 +/- 0.82 (95 % CI: 0.97-1.38) to 0.99 +/- 0.83 (95 % CI: 0.78-1.2) (p-value = 0.0009) and in the CTR group (group two) from 1.74 +/- 0.81 (95 % CI: 1.42-2.1) to 1.66 +/-

0.90 (95 % CI: 1.3-2.03) (p-value = 0.31), respectively. Secondary cataract was observed in a total of 44 eyes (50%), of which 34 (38.6%) were of group one and 10 (8.8%) of group two. CCS was seen in a total of 6 eyes (7%) all of group one. CME was noted in 3 eyes (3.4%), of which 2 belonged to group one and a second 1 to group two. Endophthalmitis was not observed in any group.

Conclusions: Both surgical approaches were of benefit to the RP patients. Eyes of group two did significantly better in respect of long-term postoperative complications. This includes secondary cataract and CCS. Eyes of group one performed significantly better in respect of visual acuity. Further research would include insights into the genetic subsets.

Keywords:

Retinitis pigmentosa

Phacoemulsification

Capsular Tension Ring

Secondary cataract

Capsular Contraction Syndrome

1
2
3
4
5
6
7
8
9
10
11
12 **INTRODUCTION:** The development of cataract is a well-known complication seen in
13 retinitis pigmentosa (RP) patients.[1-4] Treatment essentially involves
14 phacoemulsification of the natural lens and the replacement by an artificial one.
15 Relatively minor lens opacities may cause disproportionate functional symptoms,
16 keeping in mind the inferior retinal function. In general, retinitis pigmentosa is an
17 important causes of blindness among working-age people.[1] This elegant method
18 leads to an increase of contrast and helps this patient group to gain visual acuity.
19 Cut-off filters may be used to improve contrast sensitivity.[2] Although, a steady
20 decrease is anticipated in the long-term prospective, surgical intervention is
21 recommended and necessary to improve quality of life. Different surgical add-ons
22 have been described in the literature to approach the potential postoperative
23 complications, one of them being the capsular contraction syndrome (CCS).[5]
24 Whether to utilize them remains to the surgeon's preference. This retrospective study
25 tried to compare the development of short- and long-term postoperative
26 complications and the best corrected visual acuity (BCVA) between two different
27 kinds of cataract surgeries. Type 1 Surgery included phacoemulsification and the
28 implantation of an intraocular lens (IOL). Type 2 Surgery adds a capsular tension ring
29 (CTR) to the inserted IOL. Postoperative complications taken into consideration were
30 intraocular pressure (IOP), cystoid macular edema (CME), secondary cataract and
31 CCS. The former two may be treated medically, whereas the latter two ask for
32 surgical intervention.
33
34
35
36
37
38
39
40
41
42
43
44
45
46
47
48
49
50
51
52
53
54
55
56
57
58
59
60

1
2
3
4
5
6
7
8
9
10
11
12
13
14
15
16
17
18
19
20
21
22
23
24
25
26
27
28
29
30
31
32
33
34
35
36
37
38
39
40
41
42
43
44
45
46
47
48
49
50
51
52
53
54
55
56
57
58
59
60

PATIENTS AND METHODS: The data of 59 patients with retinitis pigmentosa who had cataract removal by two different kinds of surgeries were retrospectively reviewed. Research was conducted according to the Tenets of the Declaration of Helsinki and with the approval of the ethics committee of Tuebingen. The first group (62 eyes) had phacoemulsification and IOL implantation. In the second group (26 eyes) a CTR was additionally inserted. Ophthalmological examinations were performed prior to surgery and at the follow-up visits. Examinations included the assessment of IOP by Goldmann tonometry, best corrected visual acuity (BCVA), anterior chamber, vitreal and retinal status. Surgeries took place between 10/2002 and 05/2010. Sex, age at surgery, preoperative findings, associated diseases, length of follow-up and postoperative complications were documented. Complications included IOP increase, CME, secondary cataract and CCS. BCVA was determined by the use of Early Treatment Diabetic Retinopathy Study (ETDRS) charts, converted into LogMAR units and recorded at the immediate preoperative visit and postoperative follow-up examinations.

PERIOPERATIVE MANAGEMENT: Preoperatively patients received antibiotics (fluoroquinolones four times daily) and corticosteroids (0.1 % dexamethasone gel four times daily) at least 24 hours prior to surgery. Postoperatively the medications were continued for up to 2 weeks or tapered, respectively.

STATISTICAL ANALYSIS: Analysis was undertaken using commercial software (JMP version 9.0). Results are presented with 95% confidence intervals (CIs). Nominal p values were calculated using *t*-test and the level of significance was set at 0.05.

RESULTS AND PATIENT CHARACTERISTICS: The mean age at surgery of our 32 male (54%) and 27 female (46%) patients was 55 years and ranged between 21 to 89 years. The overall mean follow-up time was 32 months (range 3 to 97 months). In group one the mean follow-up period was 37 months (range 3 to 97 months) and in group two 24 months (range 3 to 60 months). The most common complication was secondary cataract occurring in 50% (44 eyes) followed by increased IOP (requiring treatment) (10%) (9 eyes), CCS (7%) (6 eyes) and CME (3.4%) (3 eyes). Group one exhibited 34 (38.6%) eyes with secondary cataract, 8 (9%) eyes with IOP elevation, 6 (7%) eyes with CCS and 2 (2.3%) eyes with CME. Group two displayed 10 eyes (8.8%) with secondary cataract and 1 (1.1%) eye with CME and elevated IOP, respectively.

Visual outcome

The group exhibited 29 (33.0 %) eyes with unchanged BCVA, 12 (13.6 %) eyes with a decrease and 47 (53.4 %) with an increase of the BCVA. The mean preoperative LogMAR BCVA in the whole group was 1.35 +/-0.84 (95 % CI: 1.17-1.53) and increased to 1.19 +/-0.90 (95 % CI: 1.0-1.38) (p-value = 0.0006). The mean preoperative and the mean postoperative LogMAR BCVA in the non-CTR group

1
2
3 improved from 1.17 +/- 0.82 (95 % CI: 0.97-1.38) to 0.99 +/- 0.83 (95 % CI: 0.78-1.2)
4
5 (p-value = 0.0009) and in the CTR group from 1.74 +/- 0.81 (95 % CI: 1.42-2.1) to
6
7 1.66 +/- 0.90 (95 % CI: 1.3-2.03) (p-value = 0.31), respectively. The pre-operative
8
9 and post-operative overview is shown in Figure 1.
10
11
12
13
14
15
16
17
18
19
20

21 **Complications**

22
23 The postoperative complications included secondary cataract, increased IOP, CCS
24 and CME in order of occurrence. An overview of the postoperative complications is
25 given in Figure 2. One patient of group one developed during the follow-up period a
26
27 subluxated IOL on her right eye. Explantation and implantation of a scleral-fixed lens
28
29 was performed (Figure 3 & 4). CCS was only seen in the group which received Type
30
31 1 Surgery (Figure 5).
32
33
34
35
36
37
38
39
40
41
42
43
44
45
46
47
48
49
50
51
52
53
54
55
56
57
58
59
60

DISCUSSION: Cataract is a common complication in RP patients. The common form
is the posterior subcapsular cataract found among all genetic subtypes.[3,4]
Fortunately treatment is straightforward and involves lens exchange surgery. This
procedure may be of great benefit to the patient, keeping in mind the inferior retinal
function (Figure 6). An improvement of the quality of life is the consequence.
Nevertheless, the potential postoperative complications may be frustrating.[6] To
address these, additional implantable devices were conceived.[5] Whether to utilize
them remains up to the surgeon's preference. This retrospective study tried to
compare BCVA and the development of short- and long-term postoperative
complications between two different kinds of cataract surgeries. Type 1 Surgery

1
2
3 included phacoemulsification and the implantation of an IOL. Type 2 Surgery adds a
4 CTR to the inserted IOL. Postoperative complications taken into consideration were
5 IOP, CME, secondary cataract and CCS.[3,4,7-14] The most common complication
6
7 was secondary cataract occurring in 50% (44 eyes) followed by increased IOP (10%)
8 (9 eyes), CCS (7%) (6 eyes) and CME (3.4%) (3 eyes). Comparing both groups a
9
10 significant reduction of secondary cataract and CCS could be observed in group two.
11
12 The mean preoperative and mean postoperative LogMAR BCVA improved in both
13
14 groups. Though in group two insignificance was noted. Thus, both surgical
15
16 approaches had beneficial outcomes for our patients in terms of decreased
17
18 postoperative complications or increased visual acuity. The decreased number of
19
20 eyes requiring IOP-lowering therapy in group two was considered a coincidence. We
21
22 had no straightforward explanation for this observation. One patient developed during
23
24 the follow-up a subluxated IOL in her right eye and several years later in her left
25
26 eye.[14,15] Bilateral severe zonular insufficiency, noted intraoperatively, was
27
28 suspected as the cause for both events.[14-16]

29
30 The additional implantation of a CTR may prevent IOL decentralization/ subluxation,
31
32 posterior capsule opacification and anterior capsular phimosis as reported by other
33
34 groups.[15,17,18] A decrease of posterior capsular opacification was also observed.
35
36 Rapid capsular phimosis may especially occur in RP patients.[19] Precautions like
37
38 CTRs should therefore be considered.[5,18] Ahmed et al reported improvements in
39
40 CTR technology enhancing the safety and efficiency in eyes with profound zonular
41
42 instability. In addition scleral-fixed devices may aid even more in decreasing
43
44 intraoperative and postoperative risks.[5]

45
46 The limitations of the current study may be the relatively small sample size of this
47
48 special subset of cataract patients. The prospective may be a future analysis of the
49
50 genetic make-up. It may be concluded that a significant reduction of secondary
51
52
53
54
55
56
57
58
59
60

1
2
3 cataract and CCS could be observed in group two and that both surgical approaches
4 had beneficial outcomes for our patients in terms of increased visual acuity or
5 decreased postoperative complications.
6
7
8
9

10 11 12 13 14 15 16 **REFERENCES:**

17
18 1 Cruciani F, Amore F, Albanese G et al. Investigation about causes of blindness and
19 low vision among members of Blind and Visually Impaired Italian Union (UICI). *Clin*
20 *Ter.* 2011;162:35-42.
21
22

23
24 2 Wetzel C, Auffarth GU, Krastel H et al. [Improving contrast sensitivity by cut-off
25 filters in high adaptation luminance levels in retinitis pigmentosa]. [Article in
26 German]. *Einfluss von Kantenfiltern auf die Kontrastempfindlichkeit bei Retinitis*
27 *pigmentosa. Ophthalmologe.* 1996;93:456-62.
28
29

30
31 3 Auffarth GU, Nimsgern C, Tetz MR et al. [Increased cataract rate and
32 characteristics of Nd:YAG laser capsulotomy in retinitis pigmentosa]. [Article in
33 German]. *Erhoehte Nachstarrate und Besonderheiten der Nd:YAG-*
34 *Laserkapsulotomie bei Retinitis pigmentosa. Ophthalmologe.* 1997;94:791-5.
35
36

37
38 4 Auffarth GU, Tetz MR, Krastel H et al. [Complicated cataracts in various forms of
39 retinitis pigmentosa. Type and incidence]. [Article in German]. *Cataracta complicata*
40 *bei verschiedenen Formen der Retinitis pigmentosa Art und Häufigkeit.*
41 *Ophthalmologe.* 1997;94:642-6.
42
43

44
45 5 Hasanee K, Butler M, Ahmed II. Capsular tension rings and related devices: current
46 concepts. *Curr Opin Ophthalmol.* 2006;17:31-41.
47
48

49
50 6 Najjar DM, Igbre AO, Tsai FF. Late capsular bag contraction and intraocular lens
51 subluxation in retinitis pigmentosa: a case report. *J Med Case Reports.* 2011;5:65.
52
53
54
55
56
57
58
59
60

1
2
3 7 Lam FC, Livingstone I, Imrie FR et al. Delayed dislocation of an injectable
4 hydrophilic acrylic lens after Nd:YAG capsulotomy in anterior capsular contraction
5 syndrome. *Cont Lens Anterior Eye*. 2011;34:193-5.
6
7

8
9
10 8 Cheour M, Brour J, Boukari M et al. Capsulorhexis contraction syndrome despite
11 capsular tension ring implantation. *Bull Soc Belge Ophtalmol*. 2010;315:19-21.
12

13
14 9 Panagopoulos A, Chalioulias K, Kirkby GR. A new approach in the surgical
15 management of anterior capsular phimosis syndrome. *Ophthalmic Res*. 2009;42:221-
16
17
18 3.
19

20
21 10 Nagy ZZ, Ecsedy M, Kovács I et al. Macular morphology assessed by optical
22 coherence tomography image segmentation after femtosecond laser-assisted and
23 standard cataract surgery. *J Cataract Refract Surg*. 2012;38:941-6.
24
25

26
27 11 Scarpa G. Bilateral cystoid macular edema after cataract surgery resolved by
28 vitrectomy. *Eur J Ophthalmol*. 2011 31;21:677-679.
29

30
31
32 12 Mansberger SL, Gordon MO, Jampel H et al. Ocular Hypertension Treatment
33 Study Group. Reduction in Intraocular Pressure after Cataract Extraction: The Ocular
34 Hypertension Treatment Study. *Ophthalmology*. 2012;119:1826-31.
35
36

37
38 13 Su WW, Chen PY, Hsiao CH et al. Primary phacoemulsification and intraocular
39 lens implantation for acute primary angle-closure. *PLoS One*. 2011;6:20056.
40
41

42
43 14 Lee HJ, Min SH, Kim TY. Bilateral spontaneous dislocation of intraocular lenses
44 within the capsular bag in a retinitis pigmentosa patient. *Korean J Ophthalmol*.
45
46
47 2004;18:52-7.
48

49
50 15 Takimoto M, Hayashi K, Hayashi H. Effect of a capsular tension ring on
51 prevention of intraocular lens decentration and tilt and on anterior capsule contraction
52 after cataract surgery. *Jpn J Ophthalmol*. 2008 ;52:363-7.
53
54
55
56
57
58
59
60

1
2
3 16 Davis D, Brubaker J, Espandar L et al. Late in-the-bag spontaneous intraocular
4 lens dislocation: evaluation of 86 consecutive cases. *Ophthalmology*. 2009;116:664-
5 70.
6
7

8
9
10 17 D'Eliseo D, Pastena B, Longanesi L et al. Prevention of posterior capsule
11 opacification using capsular tension ring for zonular defects in cataract surgery. *Eur J*
12 *Ophthalmol*. 2003;13:151-4.
13
14

15
16 18 Hasanee K, Ahmed II. Capsular tension rings: update on endocapsular support
17 devices. *Ophthalmol Clin North Am*. 2006;19:507-19.
18
19

20
21 19 Nikpoor N, Stone DU. Rapid capsular phimosis in retinitis pigmentosa. *Ophthalmic*
22 *Surg Lasers Imaging*. 2010;41.
23
24
25
26
27
28
29
30
31
32
33
34
35
36
37
38
39
40
41
42
43
44
45
46
47
48
49
50
51
52
53
54
55
56
57
58
59
60

FIGURES:

Figure 1:

Preoperative and postoperative Visus in LogMAR for the total group, Type 2 and Type 1 Surgery.

Figure 2:

Figure 3 & 4:

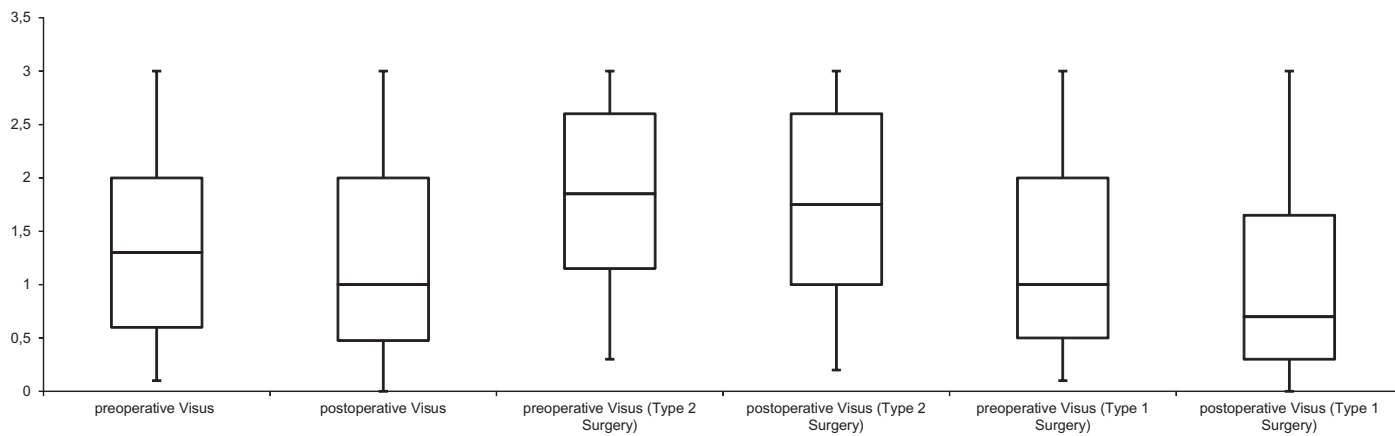
Demonstrate the IOL dislocation of the one patient with bilateral severe zonular insufficiency and the scleral-fixed IOL of the fellow eye.

Figure 5:

Depicts the developed capsular phimosis in a patient belonging to group one, which did not receive additional CTR insertion.

Figure 6:

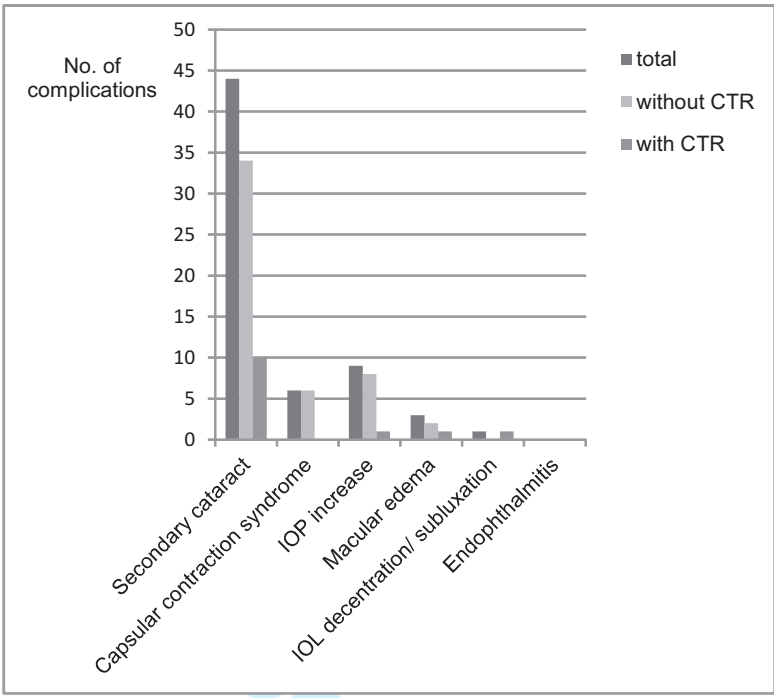
Pathognomic retinal changes in a retinitis pigmentosa patient.



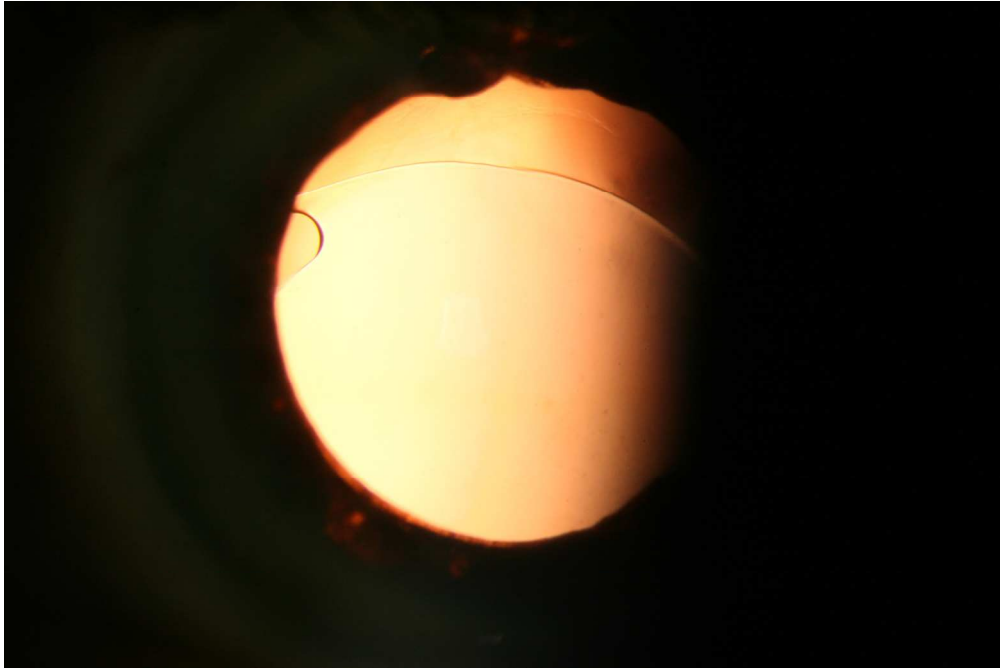
For peer review only

1
2
3
4
5
6
7
8
9
10
11
12
13
14
15
16
17
18
19
20
21
22
23
24
25
26
27
28
29
30
31
32
33
34
35
36
37
38
39
40
41
42
43
44
45
46
47
48
49
50
51
52
53
54
55
56
57
58
59
60

1
2
3
4
5
6
7
8
9
10
11
12
13
14
15
16
17
18
19
20
21
22
23
24
25
26
27
28
29
30
31
32
33
34
35
36
37
38
39
40
41
42
43
44
45
46
47
48
49
50
51
52
53
54
55
56
57
58
59
60



For peer review only



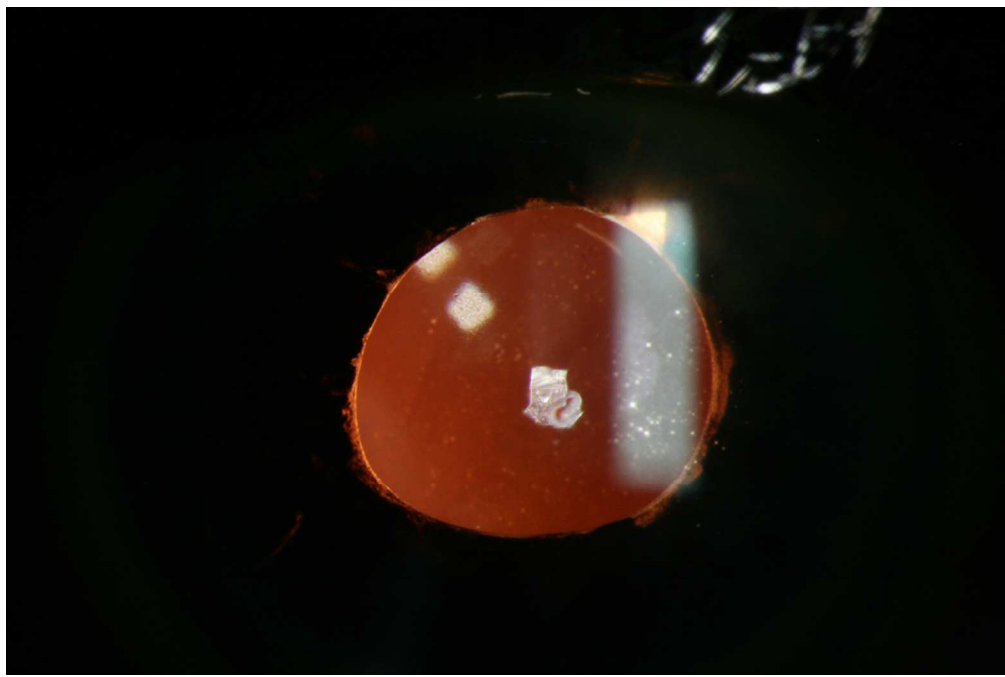
Demonstrates the IOL dislocation of the one patient with bilateral severe zonular insufficiency.

101x67mm (300 x 300 DPI)

view only

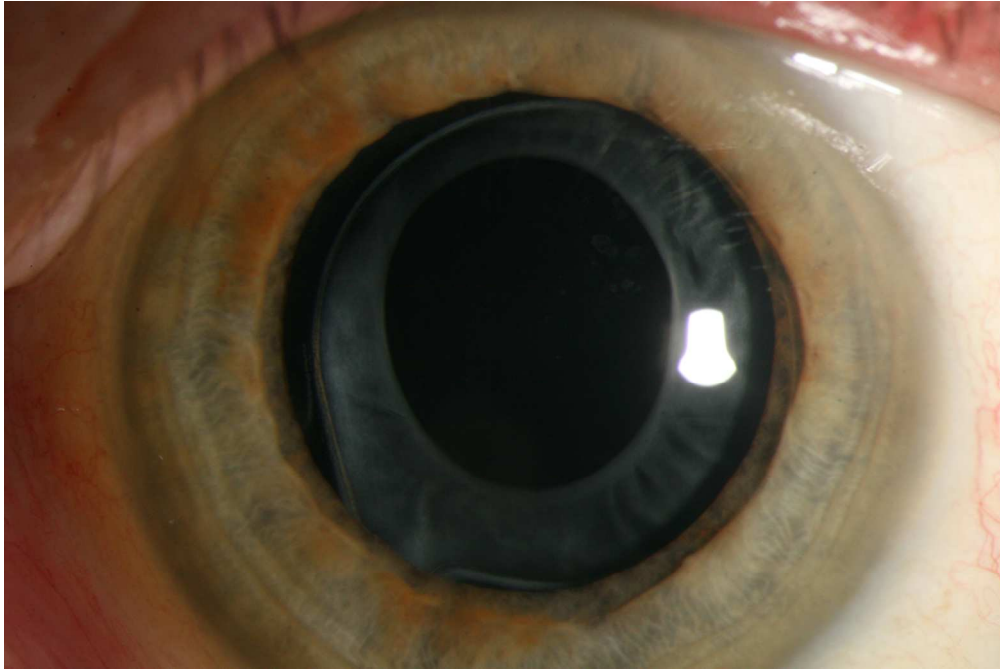
1
2
3
4
5
6
7
8
9
10
11
12
13
14
15
16
17
18
19
20
21
22
23
24
25
26
27
28
29
30
31
32
33
34
35
36
37
38
39
40
41
42
43
44
45
46
47
48
49
50
51
52
53
54
55
56
57
58
59
60

1
2
3
4
5
6
7
8
9
10
11
12
13
14
15
16
17
18
19
20
21
22
23
24
25
26
27
28
29
30
31
32
33
34
35
36
37
38
39
40
41
42
43
44
45
46
47
48
49
50
51
52
53
54
55
56
57
58
59
60



Demonstrates the scleral-fixed IOL of the fellow eye in the one patient with bilateral severe zonular insufficiency.
101x67mm (300 x 300 DPI)

view only

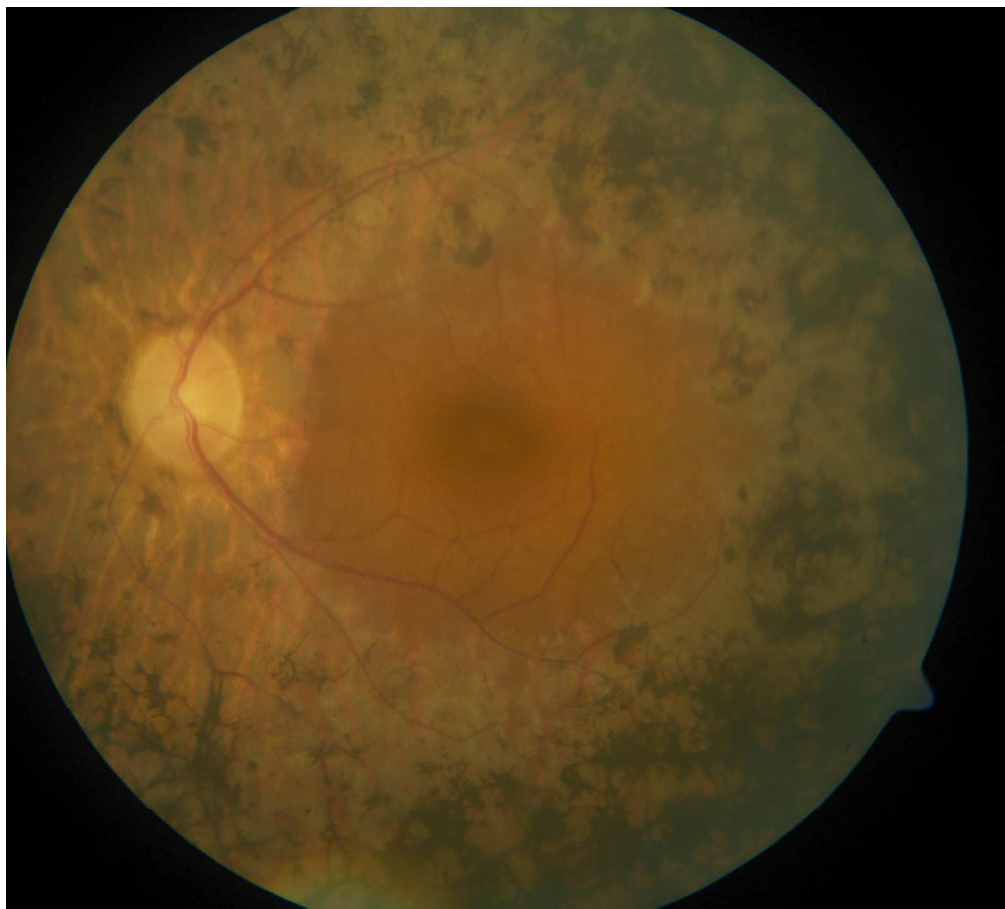

Depicts the developed capsular phimosis in a patient belonging to group one, which did not receive additional CTR insertion.
101x67mm (300 x 300 DPI)

view only

1
2
3
4
5
6
7
8
9
10
11
12
13
14
15
16
17
18
19
20
21
22
23
24
25
26
27
28
29
30
31
32
33
34
35
36
37
38
39
40
41
42
43
44
45
46
47
48
49
50
51
52
53
54
55
56
57
58
59
60

1
2
3
4
5
6
7
8
9
10
11
12
13
14
15
16
17
18
19
20
21
22
23
24
25
26
27
28
29
30
31
32
33
34
35
36
37
38
39
40
41
42
43
44
45
46
47
48
49
50
51
52
53
54
55
56
57
58
59
60



Pathognomonic retinal changes in a retinitis pigmentosa patient.
101x91mm (300 x 300 DPI)

only



Long-term clinical Results after Cataract Surgery with and without capsular Tension Ring in Patients with Retinitis Pigmentosa: A retrospective Study

Journal:	<i>BMJ Open</i>
Manuscript ID:	bmjopen-2013-002616.R1
Article Type:	Research
Date Submitted by the Author:	03-Mar-2013
Complete List of Authors:	Bayyoud, Tarek; Eberhard-Karls-University, University Eye Hospital Bartz-Schmidt, Karl; Eberhardt-Karls-University, University Eye Hospital Yoeruek, Efdal; Eberhardt-Karls-University, University Eye Hospital
Primary Subject Heading:	Ophthalmology
Secondary Subject Heading:	Genetics and genomics, Surgery
Keywords:	Retinitis pigmentosa, Capsular Tension Ring, Capsular Contraction Syndrome, Phacoemulsification, Secondary cataract

SCHOLARONE™
Manuscripts

1
2
3
4
5
6
7
8
9
10
11
12
13
14
15
16
17
18
19
20
21
22
23
24
25
26
27
28
29
30
31
32
33
34
35
36
37
38
39
40
41
42
43
44
45
46
47
48
49
50
51
52
53
54
55
56
57
58
59
60

Long-term clinical Results after Cataract Surgery with and without capsular Tension Ring in Patients with Retinitis Pigmentosa: A retrospective Study

Tarek Bayyoud, MD, Karl Ulrich Bartz- Schmidt, MD, Efdal Yoeruek, MD.

Department of Ophthalmology, Eberhard-Karls University Tuebingen, Germany.

Corresponding author:

Tarek Bayyoud, University Eye Hospital, Department of Ophthalmology, Eberhard-Karls University, Schleichstr. 12, 72076 Tuebingen, Germany; Phone+49-7071-2983728, Fax+49-7071-294674. tarek_bayyoud@gmx.de

T. Bayyoud, None; KU Bartz-Schmidt, None; E. Yoeruek, None.

Funding statement: This research received no specific grant from any funding agency in the public, commercial or not-for-profit sectors. The authors declare that they have no competing interests.

Contributorship statement: Contributors: Bayyoud acquisition of data, cleaned and analysed the data, wrote the statistical analysis plan, drafted and revised the paper and was involved in final approval. Yoeruek conceptualized the project, monitored data collection, drafted and revised the paper and was involved in final approval. Bartz-Schmidt contributed to conception, revised the draft paper and was involved in final approval.

Competing Interests

None

Data sharing

No additional unpublished data

Word count: 1817

ARTICLE SUMMARY

Article Summary: *Long-term clinical Results after Cataract Surgery with and without capsular Tension Ring in Patients with Retinitis Pigmentosa: A retrospective Study*

Article Focus:

- Long-term clinical outcomes after cataract surgery with and without capsular tension ring in a group of retinitis pigmentosa patients

Key messages:

- Both surgical approaches were of benefit to retinitis pigmentosa patients
- Surgery with capsular tension ring implantation resulted in fewer long-term postoperative complications including secondary cataract and capsular contraction syndrome

Strength and limitations:

- Relatively small sample size of this special subset of cataract patients

ABSTRACT

Objectives: To describe the long-term clinical outcomes after cataract surgery with and without capsular tension ring (CTR) in a group of retinitis pigmentosa (RP) patients

Design: Retrospective study

Setting: Tertiary referral center

Participants: 52 eyes (46 patients) with RP

Interventions: Cataract surgery was undertaken between 10/2002 and 05/2010

Primary and secondary outcome measures: Visual acuity, secondary cataract, capsular contraction syndrome (CCS), intraocular pressure, cystoid macular edema (CME), intraocular lens dislocation and endophthalmitis

Results: The mean age at surgery was about 53 years and the overall mean follow-up 26 months (range 3-60 months). The mean preoperative LogMAR BCVA in the whole group was 1.45 +/-0.85 (95 % CI: 1.21-1.69) and increased to 1.32 +/-0.95 (95 % CI: 1.06-1.58) (p-value = 0.02). The mean preoperative and the mean postoperative LogMAR BCVA in the non-CTR group (group one) improved from 1.16 +/- 0.8 (95 % CI: 0.83-1.48) to 0.98 +/- 0.88 (95 % CI: 0.62-1.33) (p-value = 0.02) and in the CTR group (group two) from 1.74 +/- 0.81 (95 % CI: 1.42-2.07) to 1.66 +/- 0.90 (95 % CI: 1.3-2.03) (p-value = 0.31), respectively. Secondary cataract was observed in a total of 23 eyes (44%), of which 13 (50%) were of group one and 10 (38%) of group two. CCS was seen in a total of 2 eyes (4%) all of group one. CME was noted in 2 eyes (4%), of which 1 belonged to group one and a second 1 to group two. Endophthalmitis was not observed in any group.

1
2
3 **Conclusions:** Both surgical approaches were of benefit to the RP patients. Eyes of
4
5 group two showed less long-term postoperative complications. This includes
6
7 secondary cataract and CCS. Eyes of group one performed significantly better in
8
9 respect of visual acuity. Further research would include insights into the genetic
10
11 subsets.
12

13
14 **Keywords:**

15 Retinitis pigmentosa

16 Phacoemulsification

17 Capsular Tension Ring

18 Secondary cataract

19 Capsular Contraction Syndrome
20
21
22
23
24
25
26
27
28
29
30
31
32
33
34
35
36
37
38
39
40
41
42
43
44
45
46
47
48
49
50
51
52
53
54
55
56
57
58
59
60

INTRODUCTION: The development of cataract is a well-known complication seen in retinitis pigmentosa (RP) patients.[1-4] Treatment essentially involves phacoemulsification of the natural lens and the replacement by an artificial one. Relatively minor lens opacities may cause disproportionate functional symptoms, keeping in mind the inferior retinal function. In general, retinitis pigmentosa is an important causes of blindness among working-age people.[1] Cataract surgery leads to an increase of contrast and helps this patient group to gain visual acuity. Cut-off filters may be used to improve contrast sensitivity.[2] Although, a steady decrease is anticipated in the long-term perspective, surgical intervention is recommended and necessary to improve quality of life. Different surgical add-ons have been described in the literature to approach the potential postoperative complications, one of them being the capsular contraction syndrome (CCS).[5] Whether to utilize them remains to the surgeon's preference. This retrospective study tried to compare the development of short- and long-term postoperative complications and the best corrected visual acuity (BCVA) between two different groups. Group one received phacoemulsification and the implantation of an intraocular lens (IOL) (Type 1 Surgery). In group two a capsular tension ring (CTR) was added to the inserted IOL (Type 2 Surgery). Postoperative complications taken into consideration were intraocular pressure (IOP), cystoid macular edema (CME), secondary cataract and CCS. The former two may be treated medically, whereas the latter two ask for surgical intervention.

PATIENTS AND METHODS: The data of 46 patients with retinitis pigmentosa who had cataract removal and phacoemulsification with or without subsequent capsular tension ring (CTR) implantation were retrospectively reviewed. Research was conducted according to the Tenets of the Declaration of Helsinki and with the approval of the ethics committee of Tuebingen. The first group (26 eyes) had phacoemulsification and IOL implantation. In the second group (26 eyes) a CTR was additionally inserted. The surgical technique involved temporally localized clear corneal incision with 2.75 mm of wound size. Experienced surgeons operated this kind of demanding cataract with the risk of zonulolysis using stop and chop technique in advanced nuclear opacity and chip and flip technique in soft cataracts. Excessive cleaning of the posterior capsule, the equatorial bag and the anterior undersurface was done in all cases. The IOL types used were all hydrophobic, acrylic lenses made of a single-piece or multi-piece. In group one 1 and 25 were 3-piece or 1-piece IOLs, respectively. In group two 10 and 16 were 3-piece or 1-piece IOLs, respectively. The CTR type was either a Croma-Pharma GmbH (Leobendorf, Austria) or Morcher GmbH (Stuttgart, Germany) fabricate of 11 mm. There were 19 emmetropic, 6 myopic and 27 hyperopic eyes. Ophthalmological examinations were performed prior to surgery and at the follow-up visits. Examinations included the assessment of IOP by Goldmann tonometry, best corrected visual acuity (BCVA), anterior chamber, vitreal and retinal status. Surgeries took place between 10/2002 and 05/2010. Sex, age at surgery, preoperative findings, associated diseases, length of follow-up and postoperative complications were documented. Complications included IOP increase, CME, secondary cataract and CCS. BCVA was determined by the use of Early Treatment Diabetic Retinopathy Study (ETDRS) charts, converted into LogMAR units and recorded at the immediate preoperative visit and postoperative follow-up examinations.

PERIOPERATIVE MANAGEMENT: Preoperatively patients received antibiotics (fluoroquinolones four times daily) and corticosteroids (0.1 % dexamethasone gel four times daily) at least 24 hours prior to surgery. Postoperatively the medications were continued for up to 2 weeks or tapered, respectively.

STATISTICAL ANALYSIS: Analysis was undertaken using commercial software (JMP version 9.0). Results are presented with 95% confidence intervals (CIs). Nominal p values were calculated using *t*-test and the level of significance was set at 0.05.

RESULTS AND PATIENT CHARACTERISTICS: The mean age at surgery of our 29 male and 23 female patients was 53 years and ranged between 21 to 89 years. The overall mean follow-up time was 26 months (range 3 to 60 months). In group one the mean follow-up period was 28 months (range 3 to 52 months) and in group two 24 months (range 3 to 60 months). The most common complication was secondary cataract occurring in 44% (23 eyes) followed by increased IOP (requiring treatment) (10%) (5 eyes), CCS (4%) (2 eyes) and CME (4%) (2 eyes). Group one exhibited 13 (50%) eyes with secondary cataract, 4 (15%) eyes with IOP elevation, 2 (8%) eyes with CCS and CME, respectively. Group two displayed 10 eyes (38%) with secondary cataract and 1 (4%) eye with CME and elevated IOP, respectively.

Visual outcome

The group exhibited 19 (37%) eyes with unchanged BCVA, 6 (12%) eyes with a decrease and 27 (52%) with an increase of the BCVA. The mean preoperative LogMAR BCVA in the whole group was 1.45 +/-0.85 (95 % CI: 1.21-1.69) and increased to 1.32 +/-0.95 (95 % CI: 1.06-1.58) (p-value = 0.02). The mean preoperative and the mean postoperative LogMAR BCVA in the non-CTR group

1
2
3 improved from 1.16 +/- 0.8 (95 % CI: 0.83-1.48) to 0.98 +/-0.88 (95 % CI: 0.62-1.33)
4
5 (p-value = 0.02) and in the CTR group from 1.74 +/- 0.81 (95 % CI: 1.42-2.07) to 1.66
6
7 +/- 0.90 (95 % CI: 1.3-2.03) (p-value = 0.31), respectively. The pre-operative and
8
9 post-operative overview is shown in Figure 1.
10

11 Complications

12
13 The postoperative complications included secondary cataract, increased IOP, CCS
14 and CME in order of occurrence. An overview of the postoperative complications is
15 given in Figure 2. In comparison, secondary cataract was seen in 50% of cases in
16 group 1 and in 38% of cases in group 2. Concerning CCS all cases were observed in
17 group 1 and no cases in group 2. IOP increase was noted in 15 % of cases in group
18 1 and 4% of cases in group 2. One patient of group one developed during the follow-
19 up period a subluxated IOL on her right eye and several years later of her left eye.
20
21 Explantation and implantation of a scleral-fixed lens was performed (Figure 3 & 4). A
22 decreased rate of secondary cataract and CCS was noted in group 2. Secondary
23 cataract was seen in 10 eyes in group 2 and 13 eyes in group 1 (p-value = 0.4). CCS
24 was only seen in the group which received Type 1 Surgery (Figure 5) (p-value =
25 0.15).
26
27
28
29
30
31
32
33
34
35
36
37
38
39
40
41
42

43 DISCUSSION: Cataract is a common complication in RP patients. The common form
44 is the posterior subcapsular cataract found among all genetic subtypes.[3,4]
45 Fortunately treatment is straightforward and involves cataract surgery. This
46 procedure may be of great benefit to the patient, keeping in mind the inferior retinal
47 function (Figure 6). An improvement of the quality of life is the consequence.
48 Nevertheless, the potential postoperative complications may be frustrating.[6] To
49 address these, additional implantable devices were conceived.[5] Whether to utilize
50 them remains up to the surgeon's preference. This retrospective study tried to
51
52
53
54
55
56
57
58
59
60

1
2
3 compare BCVA and the development of short- and long-term postoperative
4 complications after cataract surgery with and without the implantation of a CTR. Type
5 1 Surgery included phacoemulsification and the implantation of an IOL. Type 2
6 Surgery adds a CTR to the inserted IOL. Postoperative complications taken into
7 consideration were IOP, CME, secondary cataract and CCS.[3,4,7-14] The most
8 common complication was secondary cataract occurring in 44% (23 eyes) followed
9 by increased IOP (10%) (6 eyes), CCS (4%) (2 eyes) and CME (4%) (2 eyes).
10 Comparing both groups less cases of secondary cataract and CCS could be
11 observed in group two. The mean preoperative and mean postoperative LogMAR
12 BCVA improved in both groups, although in group two the difference was not
13 statistically significant. Group one performed better in terms of final vision. This might
14 be explained by the decreased, pre-operative visual acuity of group two. Thus, both
15 surgical approaches had beneficial outcomes for our patients in terms of a low rate of
16 postoperative complications or increased visual acuity. The decreased number of
17 eyes requiring IOP-lowering therapy in group two was considered a coincidence. 5
18 eyes received anti-glaucoma therapy. We had no straightforward explanation for this
19 observation. In the one case with bilateral subluxated IOL severe zonular
20 insufficiency, noted intraoperatively, was suspected as the cause.[14-16]

21
22 The additional implantation of a CTR may prevent IOL decentralization/ subluxation,
23 posterior capsule opacification and anterior capsular phimosis as reported by other
24 groups.[15,17,18] A decrease of posterior capsular opacification was also observed.
25 Rapid capsular phimosis may especially occur in RP patients.[19] Precautions like
26 CTRs should therefore be considered.[5,18] Ahmed et al reported improvements in
27 CTR technology enhancing the safety and efficiency in eyes with profound zonular
28 instability. In addition scleral-fixed devices may aid even more in decreasing
29 intraoperative and postoperative risks.[5] Nevertheless, there are also reports in the
30
31
32
33
34
35
36
37
38
39
40
41
42
43
44
45
46
47
48
49
50
51
52
53
54
55
56
57
58
59
60

1
2
3 literature stating fibrotic reactions, regarding PCO and CCS, and dislocations in
4 patients with zonular weakness.[20-22]
5
6

7 The limitations of the current study may be the relatively small sample size of this
8 special subset of cataract patients. Further studies may try to include more cases or
9 an analysis of the different genetic subtypes of retinitis pigmentosa. It may be
10 concluded that less cases of secondary cataract and CCS could be observed in
11 group two and that both surgical approaches had beneficial outcomes for our patients
12 in terms of increased visual acuity or decreased postoperative complications.
13
14
15
16
17
18
19
20
21
22
23
24
25
26
27
28
29
30
31
32
33
34
35
36
37
38
39
40
41
42
43
44
45
46
47
48
49
50
51
52
53
54
55
56
57
58
59
60

REFERENCES:

- 1 Cruciani F, Amore F, Albanese G et al. Investigation about causes of blindness and low vision among members of Blind and Visually Impaired Italian Union (UICI). *Clin Ter.* 2011;162:35-42.
- 2 Wetzel C, Auffarth GU, Krastel H et al. [Improving contrast sensitivity by cut-off filters in high adaptation luminance levels in retinitis pigmentosa]. [Article in German]. Einfluss von Kantenfiltern auf die Kontrastempfindlichkeit bei Retinitis pigmentosa. *Ophthalmologe.* 1996;93:456-62.
- 3 Auffarth GU, Nimsgern C, Tetz MR et al. [Increased cataract rate and characteristics of Nd:YAG laser capsulotomy in retinitis pigmentosa]. [Article in German]. Erhoehte Nachstarrate und Besonderheiten der Nd:YAG-Laserkapsulotomie bei Retinitis pigmentosa. *Ophthalmologe.* 1997;94:791-5.
- 4 Auffarth GU, Tetz MR, Krastel H et al. [Complicated cataracts in various forms of retinitis pigmentosa. Type and incidence]. [Article in German]. Cataracta complicata bei verschiedenen Formen der Retinitis pigmentosa Art und Häufigkeit. *Ophthalmologe.* 1997;94:642-6.
- 5 Hasanee K, Butler M, Ahmed II. Capsular tension rings and related devices: current concepts. *Curr Opin Ophthalmol.* 2006;17:31-41.
- 6 Najjar DM, Igbre AO, Tsai FF. Late capsular bag contraction and intraocular lens subluxation in retinitis pigmentosa: a case report. *J Med Case Reports.* 2011;5:65.
- 7 Lam FC, Livingstone I, Imrie FR et al. Delayed dislocation of an injectable hydrophilic acrylic lens after Nd:YAG capsulotomy in anterior capsular contraction syndrome. *Cont Lens Anterior Eye.* 2011;34:193-5.
- 8 Cheour M, Brour J, Boukari M et al. Capsulorhexis contraction syndrome despite capsular tension ring implantation. *Bull Soc Belge Ophtalmol.* 2010;315:19-21.

1
2
3 9 Panagopoulos A, Chalioulias K, Kirkby GR. A new approach in the surgical
4 management of anterior capsular phimosis syndrome. *Ophthalmic Res.* 2009;42:221-
5
6
7 3.

8
9
10 10 Nagy ZZ, Ecsedy M, Kovács I et al. Macular morphology assessed by optical
11 coherence tomography image segmentation after femtosecond laser-assisted and
12 standard cataract surgery. *J Cataract Refract Surg.* 2012;38:941-6.
13
14

15
16 11 Scarpa G. Bilateral cystoid macular edema after cataract surgery resolved by
17 vitrectomy. *Eur J Ophthalmol.* 2011 31;21:677-679.
18
19

20
21 12 Mansberger SL, Gordon MO, Jampel H et al. Ocular Hypertension Treatment
22 Study Group. Reduction in Intraocular Pressure after Cataract Extraction: The Ocular
23 Hypertension Treatment Study. *Ophthalmology.* 2012;119:1826-31.
24
25

26
27 13 Su WW, Chen PY, Hsiao CH et al. Primary phacoemulsification and intraocular
28 lens implantation for acute primary angle-closure. *PLoS One.* 2011;6:20056.
29
30

31
32 14 Lee HJ, Min SH, Kim TY. Bilateral spontaneous dislocation of intraocular lenses
33 within the capsular bag in a retinitis pigmentosa patient. *Korean J Ophthalmol.*
34 2004;18:52-7.
35
36

37
38 15 Takimoto M, Hayashi K, Hayashi H. Effect of a capsular tension ring on
39 prevention of intraocular lens decentration and tilt and on anterior capsule contraction
40 after cataract surgery. *Jpn J Ophthalmol.* 2008 ;52:363-7.
41
42

43
44 16 Davis D, Brubaker J, Espandar L et al. Late in-the-bag spontaneous intraocular
45 lens dislocation: evaluation of 86 consecutive cases. *Ophthalmology.* 2009;116:664-
46
47
48 70.
49

50
51 17 D'Eliseo D, Pastena B, Longanesi L et al. Prevention of posterior capsule
52 opacification using capsular tension ring for zonular defects in cataract surgery. *Eur J*
53
54
55
56
57
58
59
60

1
2
3 18 Hasanee K, Ahmed II. Capsular tension rings: update on endocapsular support
4 devices. *Ophthalmol Clin North Am*. 2006;19:507-19.
5

6
7 19 Nikpoor N, Stone DU. Rapid capsular phimosis in retinitis pigmentosa. *Ophthalmic*
8
9 *Surg Lasers Imaging*. 2010Jul29;41 online.
10

11 20 Masket S, Osher R. Late complications with intraocular lens dislocation after
12 capsulorhexis in pseudoexfoliation syndrome. *J Cataract Refract Surg*.
13 2002;28:1482-1484.
14

15
16 21 Sudhir R, Rao S. Capsulorhexis phimosis in retinitis pigmentosa despite capsular
17
18 tension ring implantation. *J Cataract Refract Surg* 2001; 27:1691-1694.
19

20
21 22 Moreno-Montanes J, et al. Complete anterior capsule contraction after
22
23 phacoemulsification with acrylic intraocular lens and endocapsular ring implantation.
24
25
26
27
28
29
30
31
32
33
34
35
36
37
38
39
40
41
42
43
44
45
46
47
48
49
50
51
52
53
54
55
56
57
58
59
60
J *Cataract Refract Surg*. 2002;28:717-719.

FIGURES:

Figure 1:

Preoperative and postoperative Vision in LogMAR for the total group, Type 2 and Type 1 Surgery.

Figure 2:

Figure 3 & 4: **(may be supplemental)**

Demonstrate the IOL dislocation of the one patient with bilateral severe zonular insufficiency and the scleral-fixed IOL of the fellow eye.

Figure 5:

Depicts the developed capsular phimosis in a patient belonging to group one, which did not receive additional CTR insertion.

Figure 6: **(may be supplemental)**

Pathognomonic retinal changes in a retinitis pigmentosa patient.

1
2
3
4
5
6
7
8
9
10
11
12
13
14
15
16
17
18
19
20
21
22
23
24
25
26
27
28
29
30
31
32
33
34
35
36
37
38
39
40
41
42
43
44
45
46
47
48
49
50
51
52
53
54
55
56
57
58
59
60

Long-term clinical Results after Cataract Surgery with and without capsular Tension Ring in Patients with Retinitis Pigmentosa: A retrospective Study

Tarek Bayyoud, MD, Karl Ulrich Bartz- Schmidt, MD, Efdal Yoeruek, MD.

Department of Ophthalmology, Eberhard-Karls University Tuebingen, Germany.

Corresponding author:

Tarek Bayyoud, University Eye Hospital, Department of Ophthalmology, Eberhard-Karls University, Schleichstr. 12, 72076 Tuebingen, Germany; Phone+49-7071-2983728, Fax+49-7071-294674. tarek_bayyoud@gmx.de

T. Bayyoud, None; KU Bartz-Schmidt, None; E. Yoeruek, None.

Funding statement: This research received no specific grant from any funding agency in the public, commercial or not-for-profit sectors. The authors declare that they have no competing interests.

Contributorship statement: Contributors: Bayyoud acquisition of data, cleaned and analysed the data, wrote the statistical analysis plan, drafted and revised the paper and was involved in final approval. Yoeruek conceptualized the project, monitored data collection, drafted and revised the paper and was involved in final approval. Bartz-Schmidt contributed to conception, revised the draft paper and was involved in final approval.

Word count: 1817

Objectives: To describe the long-term clinical outcomes after cataract surgery with and without capsular tension ring (CTR) in a group of retinitis pigmentosa (RP) patients

Design: Retrospective study

Setting: Tertiary referral center

Participants: 52 eyes (46 patients) with RP

Interventions: Cataract surgery was undertaken between 10/2002 and 05/2010

Primary and secondary outcome measures: Visual acuity, secondary cataract, capsular contraction syndrome (CCS), intraocular pressure, cystoid macular edema (CME), intraocular lens dislocation and endophthalmitis

Results: The mean age at surgery was about 53 years and the overall mean follow-up 26 months (range 3-60 months). The mean preoperative LogMAR BCVA in the whole group was 1.45 +/-0.85 (95 % CI: 1.21-1.69) and increased to 1.32 +/-0.95 (95 % CI: 1.06-1.58) (p-value = 0.02). The mean preoperative and the mean postoperative LogMAR BCVA in the non-CTR group (group one) improved from 1.16 +/- 0.8 (95 % CI: 0.83-1.48) to 0.98 +/- 0.88 (95 % CI: 0.62-1.33) (p-value = 0.02) and in the CTR group (group two) from 1.74 +/- 0.81 (95 % CI: 1.42-2.07) to 1.66 +/- 0.90 (95 % CI: 1.3-2.03) (p-value = 0.31), respectively. Secondary cataract was observed in a total of 23 eyes (44%), of which 13 (50%) were of group one and 10 (38%) of group two. CCS was seen in a total of 2 eyes (4%) all of group one. CME was noted in 2 eyes (4%), of which 1 belonged to group one and a second 1 to group two. Endophthalmitis was not observed in any group.

1
2
3 **Conclusions:** Both surgical approaches were of benefit to the RP patients. Eyes of
4 group two **showed less long-term postoperative complications.** This includes
5 secondary cataract and CCS. Eyes of group one performed significantly better in
6 respect of visual acuity. Further research would include insights into the genetic
7 subsets.
8
9
10
11
12

13
14
15 **Keywords:**

16 Retinitis pigmentosa

17 Phacoemulsification

18 Capsular Tension Ring

19 Secondary cataract

20 Capsular Contraction Syndrome
21
22
23
24
25
26
27
28
29
30
31
32
33
34
35
36
37
38
39
40
41
42
43
44
45
46
47
48
49
50
51
52
53
54
55
56
57
58
59
60

1
2
3 **INTRODUCTION:** The development of cataract is a well-known complication seen in
4 retinitis pigmentosa (RP) patients.[1-4] Treatment essentially involves
5 phacoemulsification of the natural lens and the replacement by an artificial one.
6
7 Relatively minor lens opacities may cause disproportionate functional symptoms,
8 keeping in mind the inferior retinal function. In general, retinitis pigmentosa is an
9 important causes of blindness among working-age people.[1] **Cataract surgery**
10 leads to an increase of contrast and helps this patient group to gain visual acuity.
11 Cut-off filters may be used to improve contrast sensitivity.[2] Although, a steady
12 decrease is anticipated in the long-term **perspective**, surgical intervention is
13 recommended and necessary to improve quality of life. Different surgical add-ons
14 have been described in the literature to approach the potential postoperative
15 complications, one of them being the capsular contraction syndrome (CCS).[5]
16 Whether to utilize them remains to the surgeon's preference. This retrospective study
17 tried to compare the development of short- and long-term postoperative
18 complications and the best corrected visual acuity (BCVA) **between two different**
19 **groups. Group one received** phacoemulsification and the implantation of an
20 intraocular lens (IOL) **(Type 1 Surgery). In group two a capsular tension ring (CTR)**
21 **was added** to the inserted IOL **(Type 2 Surgery)**. Postoperative complications taken
22 into consideration were intraocular pressure (IOP), cystoid macular edema (CME),
23 secondary cataract and CCS. The former two may be treated medically, whereas the
24 latter two ask for surgical intervention.
25
26
27
28
29
30
31
32
33
34
35
36
37
38
39
40
41
42
43
44
45
46
47
48
49
50
51
52
53
54
55
56
57
58
59
60

PATIENTS AND METHODS: The data of **46** patients with retinitis pigmentosa who had cataract removal **and phacoemulsification with or without subsequent capsular tension ring (CTR) implantation** were retrospectively reviewed. Research was conducted according to the Tenets of the Declaration of Helsinki and with the approval of the ethics committee of Tuebingen. The first group (**26** eyes) had phacoemulsification and IOL implantation. In the second group (26 eyes) a CTR was additionally inserted. **The surgical technique involved temporally localized clear corneal incision with 2.75 mm of wound size. Experienced surgeons operated this kind of demanding cataract with the risk of zonulolysis using stop and chop technique in advanced nuclear opacity and chip and flip technique in soft cataracts. Excessive cleaning of the posterior capsule, the equatorial bag and the anterior undersurface was done in all cases. The IOL types used were all hydrophobic, acrylic lenses made of a single-piece or multi-piece. In group one 1 and 25 were 3-piece or 1-piece IOLs, respectively. In group two 10 and 16 were 3-piece or 1-piece IOLs, respectively. The CTR type was either a Croma-Pharma GmbH (Leobendorf, Austria) or Morcher GmbH (Stuttgart, Germany) fabricate of 11 mm. There were 19 emmetropic, 6 myopic and 27 hyperopic eyes.** Ophthalmological examinations were performed prior to surgery and at the follow-up visits. Examinations included the assessment of IOP by Goldmann tonometry, best corrected visual acuity (BCVA), anterior chamber, vitreal and retinal status. Surgeries took place between 10/2002 and 05/2010. Sex, age at surgery, preoperative findings, associated diseases, length of follow-up and postoperative complications were documented. Complications included IOP increase, CME, secondary cataract and CCS. BCVA was determined by the use of Early Treatment Diabetic Retinopathy Study (ETDRS) charts, converted into LogMAR units and

1
2
3 recorded at the immediate preoperative visit and postoperative follow-up
4
5 examinations.
6
7

8 **PERIOPERATIVE MANAGEMENT:** Preoperatively patients received antibiotics
9
10 (fluoroquinolones four times daily) and corticosteroids (0.1 % dexamethasone gel
11
12 four times daily) at least 24 hours prior to surgery. Postoperatively the medications
13
14 were continued for up to 2 weeks or tapered, respectively.
15
16
17

18
19 **STATISTICAL ANALYSIS:** Analysis was undertaken using commercial software
20
21 (JMP version 9.0). Results are presented with 95% confidence intervals (CIs).
22
23 Nominal p values were calculated using *t*-test and the level of significance was set at
24
25 0.05.
26
27

28
29 **RESULTS AND PATIENT CHARACTERISTICS:** The mean age at surgery of our **29**
30
31 **male** and **23 female** patients was **53** years and ranged between **21 to 89 years**. The
32
33 overall mean follow-up time was **26** months (**range 3 to 60 months**). In group one
34
35 the mean follow-up period was **28 months (range 3 to 52 months)** and in group two
36
37 24 months (range 3 to 60 months). The most common complication was secondary
38
39 cataract occurring in **44% (23 eyes)** followed by increased IOP (requiring treatment)
40
41 **(10%) (5 eyes), CCS (4%) (2 eyes) and CME (4%) (2 eyes)**. Group one exhibited **13**
42
43 **(50%)** eyes with secondary cataract, **4 (15%)** eyes with IOP elevation, **2 (8%)** eyes
44
45 with CCS and CME, respectively. Group two displayed 10 eyes (38%) with secondary
46
47 cataract and 1 (4%) eye with CME and elevated IOP, respectively.
48
49
50

51 **Visual outcome**

52
53
54 The group exhibited **19 (37%)** eyes with unchanged BCVA, **6 (12%)** eyes with a
55
56 decrease and **27 (52%)** with an increase of the BCVA. **The mean preoperative**
57
58 **LogMAR BCVA in the whole group was 1.45 +/-0.85 (95 % CI: 1.21-1.69) and**
59
60

1
2
3 increased to 1.32 +/-0.95 (95 % CI: 1.06-1.58) (p-value = 0.02). The mean
4 preoperative and the mean postoperative LogMAR BCVA in the non-CTR group
5 improved from 1.16 +/- 0.8 (95 % CI: 0.83-1.48) to 0.98 +/-0.88 (95 % CI: 0.62-
6 1.33) (p-value = 0.02) and in the CTR group from 1.74 +/- 0.81 (95 % CI: 1.42-
7 2.07) to 1.66 +/- 0.90 (95 % CI: 1.3-2.03) (p-value = 0.31), respectively. The pre-
8 operative and post-operative overview is shown in Figure 1.

15 Complications

16
17 The postoperative complications included secondary cataract, increased IOP, CCS
18 and CME in order of occurrence. An overview of the postoperative complications is
19 given in Figure 2. **In comparison, secondary cataract was seen in 50% of cases**
20 **in group 1 and in 38% of cases in group 2. Concerning CCS all cases were**
21 **observed in group 1 and no cases in group 2. IOP increase was noted in 15 %**
22 **of cases in group 1 and 4% of cases in group 2. One patient of group one**
23 **developed during the follow-up period a subluxated IOL on her right eye and**
24 **several years later of her left eye.** Explantation and implantation of a scleral-fixed
25 lens was performed (Figure 3 & 4). **A decreased rate of secondary cataract and**
26 **CCS was noted in group 2. Secondary cataract was seen in 10 eyes in group 2**
27 **and 13 eyes in group 1 (p-value = 0.4). CCS was only seen in the group which**
28 **received Type 1 Surgery (Figure 5) (p-value = 0.15).**

29
30
31
32
33
34
35
36
37
38
39
40
41
42
43
44
45
46
47 **DISCUSSION:** Cataract is a common complication in RP patients. The common form
48 is the posterior subcapsular cataract found among all genetic subtypes.[3,4]
49 Fortunately treatment is straightforward and involves **cataract surgery**. This
50 procedure may be of great benefit to the patient, keeping in mind the inferior retinal
51 function (Figure 6). An improvement of the quality of life is the consequence.
52
53
54
55
56
57
58
59
60 Nevertheless, the potential postoperative complications may be frustrating.[6] To

1
2
3 address these, additional implantable devices were conceived.[5] Whether to utilize
4 them remains up to the surgeon's preference. **This retrospective study tried to**
5 **compare BCVA and the development of short- and long-term postoperative**
6 **complications after cataract surgery with and without the implantation of a**
7 **CTR.** Type 1 Surgery included phacoemulsification and the implantation of an IOL.
8 Type 2 Surgery adds a CTR to the inserted IOL. Postoperative complications taken
9 into consideration were IOP, CME, secondary cataract and CCS.[3,4,7-14] The most
10 common complication was secondary cataract occurring in **44% (23 eyes)** followed
11 by increased IOP **(10%) (6 eyes)**, CCS **(4%) (2 eyes)** and CME **(4%) (2 eyes)**.
12 Comparing both groups **less cases of** secondary cataract and CCS could be
13 observed in group two. The mean preoperative and mean postoperative LogMAR
14 BCVA improved in both groups, **although in group two the difference was not**
15 **statistically significant. Group one performed better in terms of final vision.**
16 **This might be explained by the decreased, pre-operative visual acuity of group**
17 **two.** Thus, both surgical approaches had beneficial outcomes for our patients in
18 terms of **a low rate of postoperative complications** or increased visual acuity. The
19 decreased number of eyes requiring IOP-lowering therapy in group two was
20 considered a coincidence. **5 eyes received anti-glaucoma therapy.** We had no
21 straightforward explanation for this observation. **In the one case with bilateral**
22 **subluxated IOL severe zonular insufficiency, noted intraoperatively, was**
23 **suspected as the cause.**[14-16]

24
25
26
27
28
29
30
31
32
33
34
35
36
37
38
39
40
41
42
43
44
45
46
47
48
49
50
51
52
53
54
55
56
57
58
59
60
The additional implantation of a CTR may prevent IOL decentralization/ subluxation,
posterior capsule opacification and anterior capsular phimosis as reported by other
groups.[15,17,18] A decrease of posterior capsular opacification was also observed.
Rapid capsular phimosis may especially occur in RP patients.[19] Precautions like
CTRs should therefore be considered.[5,18] Ahmed et al reported improvements in

1
2
3 CTR technology enhancing the safety and efficiency in eyes with profound zonular
4 instability. In addition scleral-fixed devices may aid even more in decreasing
5 intraoperative and postoperative risks.[5] **Nevertheless, there are also reports in**
6
7
8
9
10 **the literature stating fibrotic reactions, regarding PCO and CCS, and**
11
12 **dislocations in patients with zonular weakness.[20-22]**

13
14 The limitations of the current study may be the relatively small sample size of this
15 special subset of cataract patients. **Further studies may try to include more cases**
16
17
18 **or an analysis of the different genetic subtypes of retinitis pigmentosa.** It may
19
20 be concluded that **less cases** of secondary cataract and CCS could be observed in
21
22 group two and that both surgical approaches had beneficial outcomes for our patients
23
24 in terms of increased visual acuity or decreased postoperative complications.
25
26
27
28
29
30
31
32
33
34
35
36
37
38
39
40
41
42
43
44
45
46
47
48
49
50
51
52
53
54
55
56
57
58
59
60

REFERENCES:

- 1 Cruciani F, Amore F, Albanese G et al. Investigation about causes of blindness and low vision among members of Blind and Visually Impaired Italian Union (UICI). *Clin Ter.* 2011;162:35-42.
- 2 Wetzel C, Auffarth GU, Krastel H et al. [Improving contrast sensitivity by cut-off filters in high adaptation luminance levels in retinitis pigmentosa]. [Article in German]. Einfluss von Kantenfiltern auf die Kontrastempfindlichkeit bei Retinitis pigmentosa. *Ophthalmologe.* 1996;93:456-62.
- 3 Auffarth GU, Nimsgern C, Tetz MR et al. [Increased cataract rate and characteristics of Nd:YAG laser capsulotomy in retinitis pigmentosa]. [Article in German]. Erhoehte Nachstarrate und Besonderheiten der Nd:YAG-Laserkapsulotomie bei Retinitis pigmentosa. *Ophthalmologe.* 1997;94:791-5.
- 4 Auffarth GU, Tetz MR, Krastel H et al. [Complicated cataracts in various forms of retinitis pigmentosa. Type and incidence]. [Article in German]. Cataracta complicata bei verschiedenen Formen der Retinitis pigmentosa Art und Häufigkeit. *Ophthalmologe.* 1997;94:642-6.
- 5 Hasanee K, Butler M, Ahmed II. Capsular tension rings and related devices: current concepts. *Curr Opin Ophthalmol.* 2006;17:31-41.
- 6 Najjar DM, Igbre AO, Tsai FF. Late capsular bag contraction and intraocular lens subluxation in retinitis pigmentosa: a case report. *J Med Case Reports.* 2011;5:65.
- 7 Lam FC, Livingstone I, Imrie FR et al. Delayed dislocation of an injectable hydrophilic acrylic lens after Nd:YAG capsulotomy in anterior capsular contraction syndrome. *Cont Lens Anterior Eye.* 2011;34:193-5.

- 1
2
3 8 Cheour M, Brour J, Boukari M et al. Capsulorhexis contraction syndrome despite
4 capsular tension ring implantation. Bull Soc Belge Ophtalmol. 2010;315:19-21.
5
6
7 9 Panagopoulos A, Chalioulias K, Kirkby GR. A new approach in the surgical
8 management of anterior capsular phimosis syndrome. Ophthalmic Res. 2009;42:221-
9
10 3.
11
12
13 10 Nagy ZZ, Ecsedy M, Kovács I et al. Macular morphology assessed by optical
14 coherence tomography image segmentation after femtosecond laser-assisted and
15 standard cataract surgery. J Cataract Refract Surg. 2012;38:941-6.
16
17
18 11 Scarpa G. Bilateral cystoid macular edema after cataract surgery resolved by
19 vitrectomy. Eur J Ophthalmol. 2011 31;21:677-679.
20
21
22 12 Mansberger SL, Gordon MO, Jampel H et al. Ocular Hypertension Treatment
23 Study Group. Reduction in Intraocular Pressure after Cataract Extraction: The Ocular
24 Hypertension Treatment Study. Ophthalmology. 2012;119:1826-31.
25
26
27 13 Su WW, Chen PY, Hsiao CH et al. Primary phacoemulsification and intraocular
28 lens implantation for acute primary angle-closure. PLoS One. 2011;6:20056.
29
30
31 14 Lee HJ, Min SH, Kim TY. Bilateral spontaneous dislocation of intraocular lenses
32 within the capsular bag in a retinitis pigmentosa patient. Korean J Ophthalmol.
33 2004;18:52-7.
34
35
36 15 Takimoto M, Hayashi K, Hayashi H. Effect of a capsular tension ring on
37 prevention of intraocular lens decentration and tilt and on anterior capsule contraction
38 after cataract surgery. Jpn J Ophthalmol. 2008 ;52:363-7.
39
40
41 16 Davis D, Brubaker J, Espandar L et al. Late in-the-bag spontaneous intraocular
42 lens dislocation: evaluation of 86 consecutive cases. Ophthalmology. 2009;116:664-
43
44
45 70.
46
47
48
49
50
51
52
53
54
55
56
57
58
59
60

1
2
3 17 D'Eliseo D, Pastena B, Longanesi L et al. Prevention of posterior capsule
4 opacification using capsular tension ring for zonular defects in cataract surgery. Eur J
5 Ophthalmol. 2003;13:151-4.
6
7

8
9
10 18 Hasanee K, Ahmed II. Capsular tension rings: update on endocapsular support
11 devices. Ophthalmol Clin North Am. 2006;19:507-19.
12

13
14 19 Nikpoor N, Stone DU. Rapid capsular phimosis in retinitis pigmentosa. Ophthalmic
15 Surg Lasers Imaging. **2010Jul29;41 online.**
16

17
18 **20 Masket S, Osher R. Late complications with intraocular lens dislocation after**
19 **capsulorhexis in pseudoexfoliation syndrome. J Cataract Refract Surg.**
20 **2002;28:1482-1484.**
21
22

23
24 **21 Sudhir R, Rao S. Capsulorhexis phimosis in retinitis pigmentosa despite**
25 **capsular tension ring implantation. J Cataract Refract Surg 2001; 27:1691-1694.**
26
27

28
29 **22 Moreno-Montanes J, et al. Complete anterior capsule contraction after**
30 **phacoemulsification with acrylic intraocular lens and endocapsular ring**
31 **implantation. J Cataract Refract Surg. 2002;28:717-719.**
32
33
34
35
36
37
38
39
40
41
42
43
44
45
46
47
48
49
50
51
52
53
54
55
56
57
58
59
60

1
2
3
4
5
6
7
8 **Article Summary:** *Long-term clinical Results after Cataract Surgery with and without*
9 *capsular Tension Ring in Patients with Retinitis Pigmentosa: A retrospective Study*
10
11

12
13 Article Focus:

- 14
15
16
17
18
19
20
21
22
23
24
25
26
27
28
29
30
31
32
33
34
35
36
37
38
39
40
41
42
43
44
45
46
47
48
49
50
51
52
53
54
55
56
57
58
59
60
- Long-term clinical outcomes after cataract surgery with and without capsular tension ring in a group of retinitis pigmentosa patients

Key messages:

- Both surgical approaches were of benefit to retinitis pigmentosa patients
- **Surgery with capsular tension ring implantation resulted in fewer long-term postoperative complications including secondary cataract and capsular contraction syndrome**

Strength and limitations:

- Relatively small sample size of this special subset of cataract patients

FIGURES:

Figure 1:

Preoperative and postoperative **Vision** in LogMAR for the total group, Type 2 and Type 1 Surgery.

Figure 2:

Figure 3 & 4: **(may be supplemental)**

Demonstrate the IOL dislocation of **the one patient** with bilateral severe zonular insufficiency and the scleral-fixed IOL of the fellow eye.

Figure 5:

Depicts the developed capsular phimosis in a patient belonging to group one, which did not receive additional CTR insertion.

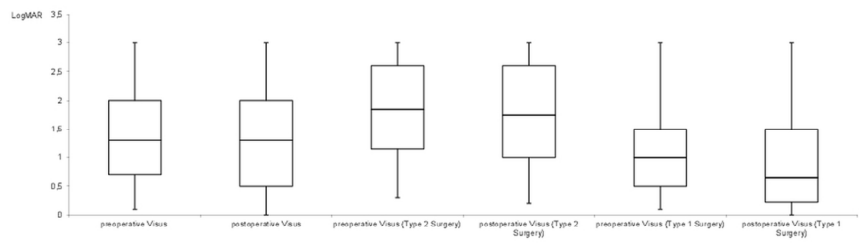
Figure 6: **(may be supplemental)**

Pathognomonic retinal changes in a retinitis pigmentosa patient.

1
2
3
4
5
6
7
8
9
10
11
12
13
14
15
16
17
18
19
20
21
22
23
24
25
26
27
28
29
30
31
32
33
34
35
36
37
38
39
40
41
42
43
44
45
46
47
48
49
50
51
52
53
54
55
56
57
58
59
60

.....

.....



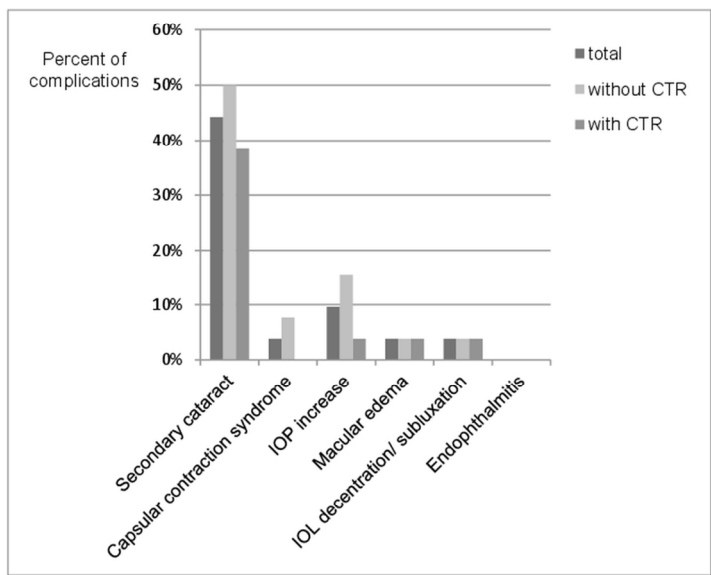
.....

.....

Preoperative and postoperative Vision in LogMAR for the total group, Type 2 and Type 1 Surgery.
116x90mm (300 x 300 DPI)

1
2
3
4
5
6
7
8
9
10
11
12
13
14
15
16
17
18
19
20
21
22
23
24
25
26
27
28
29
30
31
32
33
34
35
36
37
38
39
40
41
42
43
44
45
46
47
48
49
50
51
52
53
54
55
56
57
58
59
60

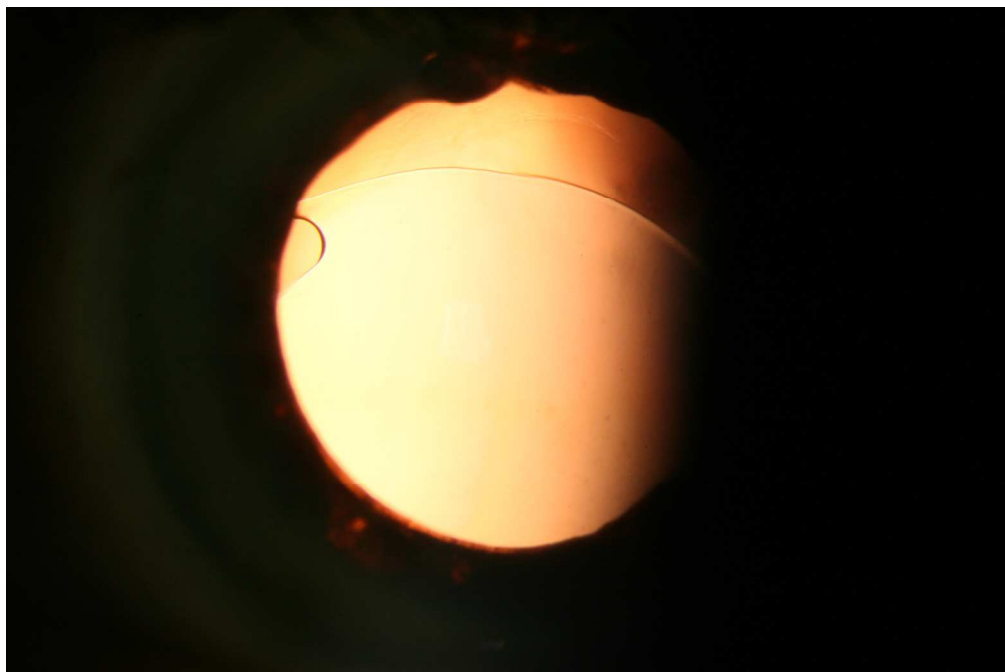
.....
.....



.....
.....

90x127mm (300 x 300 DPI)

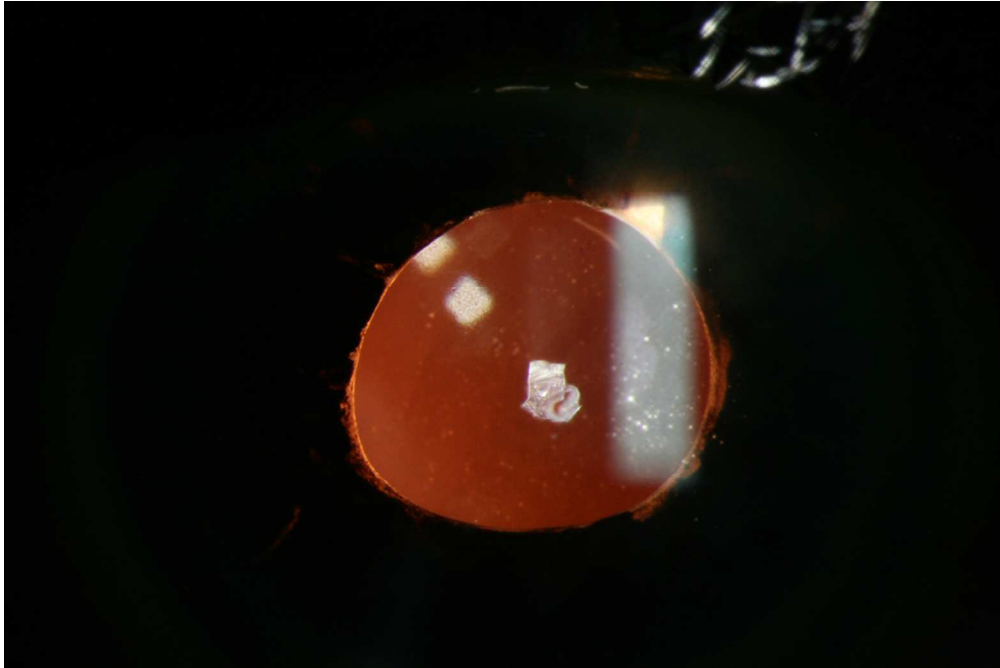
1
2
3
4
5
6
7
8
9
10
11
12
13
14
15
16
17
18
19
20
21
22
23
24
25
26
27
28
29
30
31
32
33
34
35
36
37
38
39
40
41
42
43
44
45
46
47
48
49
50
51
52
53
54
55
56
57
58
59
60



Demonstrates the IOL dislocation of the one patient with bilateral severe zonular insufficiency.

101x67mm (300 x 300 DPI)

view only

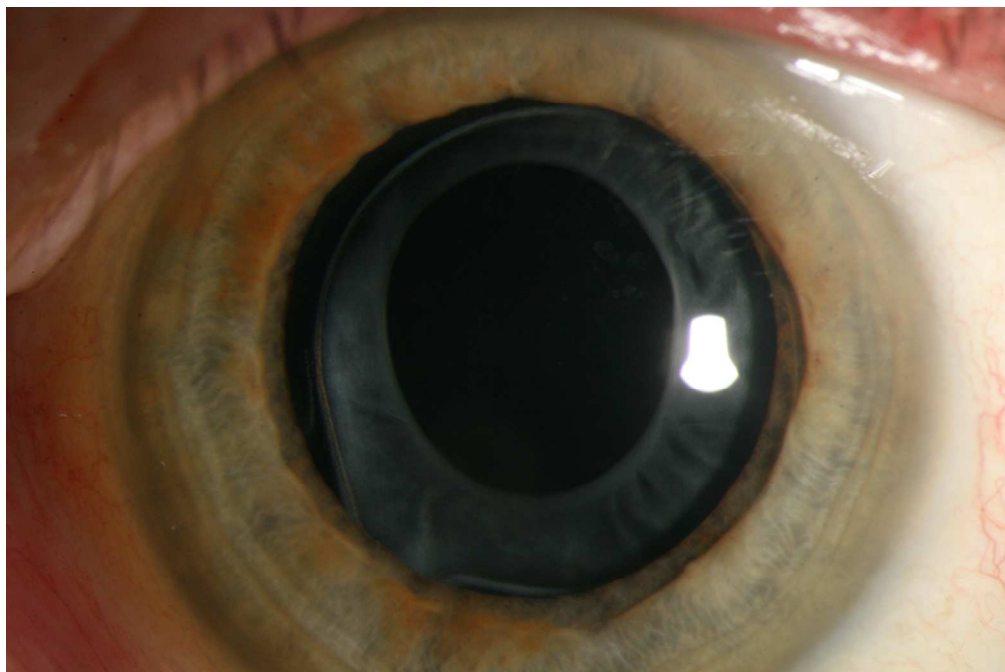


Demonstrates the scleral-fixed IOL of the fellow eye in the one patient with bilateral severe zonular insufficiency.
101x67mm (300 x 300 DPI)

view only

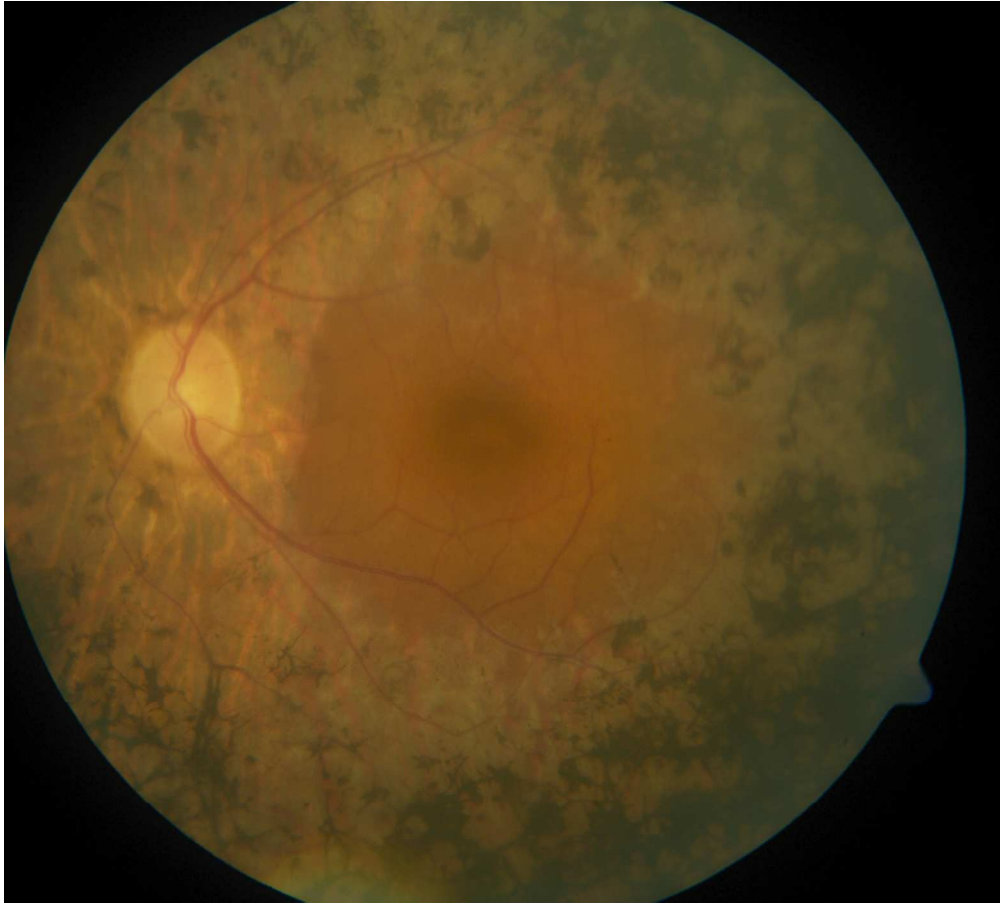1
2
3
4
5
6
7
8
9
10
11
12
13
14
15
16
17
18
19
20
21
22
23
24
25
26
27
28
29
30
31
32
33
34
35
36
37
38
39
40
41
42
43
44
45
46
47
48
49
50
51
52
53
54
55
56
57
58
59
60

1
2
3
4
5
6
7
8
9
10
11
12
13
14
15
16
17
18
19
20
21
22
23
24
25
26
27
28
29
30
31
32
33
34
35
36
37
38
39
40
41
42
43
44
45
46
47
48
49
50
51
52
53
54
55
56
57
58
59
60



Depicts the developed capsular phimosis in a patient belonging to group one, which did not receive additional CTR insertion.
101x67mm (300 x 300 DPI)

view only



Pathognomonic retinal changes in a retinitis pigmentosa patient.
101x91mm (300 x 300 DPI)

only

1
2
3
4
5
6
7
8
9
10
11
12
13
14
15
16
17
18
19
20
21
22
23
24
25
26
27
28
29
30
31
32
33
34
35
36
37
38
39
40
41
42
43
44
45
46
47
48
49
50
51
52
53
54
55
56
57
58
59
60