

BMJ Open Chest radiography for simplified evaluation of central venous catheter tip positioning for safe and accurate haemodynamic monitoring: a retrospective observational study

Minwoo Kang,¹ Jinkun Bae,¹ Sujin Moon,² Tae Nyoung Chung ¹

To cite: Kang M, Bae J, Moon S, *et al*. Chest radiography for simplified evaluation of central venous catheter tip positioning for safe and accurate haemodynamic monitoring: a retrospective observational study. *BMJ Open* 2021;**11**:e041101. doi:10.1136/bmjopen-2020-041101

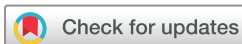► Prepublication history for this paper is available online. To view the files, please visit the journal online (<http://dx.doi.org/10.1136/bmjopen-2020-041101>).

MK and JB contributed equally.

Received 02 June 2020

Revised 01 December 2020

Accepted 01 December 2020



© Author(s) (or their employer(s)) 2021. Re-use permitted under CC BY-NC. No commercial re-use. See rights and permissions. Published by BMJ.

¹Department of Emergency Medicine, CHA Bundang Medical Center, CHA University, Seongnam-Si, Gyeonggi-do, Republic of Korea

²School of Medicine, CHA University, Seongnam-Si, Gyeonggi-do, Republic of Korea

Correspondence to

Dr Tae Nyoung Chung; hendrix74@gmail.com

ABSTRACT

Objectives The tip-to-carina (TC) distance on a simple chest X-ray (CXR) has proven value in the determination of correct central venous catheter (CVC) positioning. However, previous studies have mostly focused on preventing the atrial insertion of the CVC tip, and not on appropriate positioning for accurate haemodynamic monitoring. We aimed to assess whether the TC distance could detect the passage of the CVC tip into the superior vena cava (SVC) and the right atrium (RA), and to accordingly suggest cut-off reference values for these two aspects.

Design Retrospective observational cohort study.

Setting Single urban tertiary level academic hospital.

Participants 479 patients who underwent CXR and chest CT scan after the insertion of a CVC with a 24-hour interval during the study period.

Intervention The TC distance was measured on CXR, and the position of the CVC tip was assessed on the chest CT images. The TC distance was described as a negative or positive number if the CVC tip was above or below the carina, respectively. Receiver-operating characteristics curve analyses were conducted to ascertain the TC distance to detect SVC entrance and RA insertion of CVC tip.

Results The TC distance could significantly detect both SVC entrance and RA insertion ($p < 0.001$ for both; area under curve 0.987 and 0.965, respectively), with a reference range of -6.69 to 15.61 mm.

Conclusion The TC distance in CXR is a simple and precise method to confirm not only the safe placement of the CVC tip but also its optimal positioning for accurate haemodynamic monitoring.

INTRODUCTION

Central venous catheter (CVC) insertion is a widely performed procedure that plays an important role in the care of critically ill patients, as well as patients who require parenteral nutrition, antibiotic therapy, chemotherapy, haemodialysis and patients with difficult peripheral venous access.¹ Central venous pressure (CVP), which is measured by CVC, is also the most frequently used

Strengths and limitations of this study

- This is the first study that suggested specific range of the tip-to-carina distance on the simple chest X-ray (CXR) to ascertain correct positioning of central venous catheter (CVC) tip in extracardiac superior vena cava.
- Our study only used the data of individuals whose CXR and CT scan were taken with same posture (both arms down), which could minimise possible errors caused by migration of CVC tip.
- Our results were derived from a retrospective analysis of the dataset from a single centre, so the generalisation of the results needs to be cautiously undertaken.

haemodynamic parameter for fluid therapy of critically ill patients.²

The superior vena cava (SVC) is the largest central vein, and the CVP can be constantly measured regardless of whether the CVC tip is within the SVC or the right atrium (RA).³ The SVC is the most suitable location to obtain CVP measurements due to the high blood flow velocity. However, if the CVC tip is inserted into RA, it may cause potentially fatal complications such as perforation, haemopericardium and cardiac tamponade.⁴⁻⁷ Therefore, the positioning of the CVC tip in the SVC such that RA insertion is prevented may be necessary for the prevention of possible fatal complications while retaining the capacity for precise CVP measurements. The lower one-third of the SVC, close to the junction of SVC and RA, is recommended as an appropriate catheter tip location.⁸

Various methods can be used to confirm the position of the CVC tip, and the gold standard is transoesophageal echocardiography (TOE). However, the TOE is rarely available in clinical practice settings, except

in specialist facilities that include a cardiac procedure room.^{9–12} Chest X-ray (CXR) is the most common tool to confirm the position of CVC tip because of its wide availability and relative low cost. Recently, point-of-care ultrasound has shown its value in the confirmation of CVC tip placement, and even showed superiority in many aspects compared with CXR.^{13–15} However, the sole use of ultrasound in real practice is restricted by various factors, and CXR is still used in almost every case of CVC tip placement.¹⁶ With a CXR, the position of the CVC tip can be confirmed relative to various anatomical landmarks in the chest.^{17–23} Among these, the tip-to-carina (TC) distance has been previously shown to be a reliable indicator in several studies.^{19,22–24} However, the studies mostly focused on the prevention of intracardiac placement of the CVC tip, but not on the confirmation of appropriate positioning of the CVC tip in the SVC, which is essential for accurate haemodynamic monitoring.

We hypothesised that the TC distance that is measured on simple CXR is appropriate for confirming the proper placement of the CVC tip, and can prevent intracardiac placement of the CVC while retaining the ability to accurately measure the haemodynamic status. We aimed to evaluate this hypothesis, and to ascertain reference values of the TC distance to facilitate the confirmation of appropriate placement of the CVC tip.

MATERIAL AND METHODS

Patient and public involvement

No patient involved.

Study population and eligibility

This study included adult patients (age ≥ 18 years) who visited the emergency department (ED) of CHA Bundang Medical Center, a tertiary-level teaching hospital with more than 85 000 yearly ED visits, between 2 January 2016 and 2 July 2018 and underwent CXR and chest CT within 24 hours of CVC insertion. The exclusion criteria were: (1) age less than 18 years, (2) abnormal chest anatomy (eg, lung cancer),²⁵ (3) difficulty in ascertaining the position of the CVC tip on a chest CT or CXR image and (4) the chest CT scan is performed with both arms raised.²⁶

Data collection

Data on patient demographics and characteristics, including the height and the weight, were obtained through a review of the EMRs. Chest CT scans were conducted on a 64-slice multidetector-row CT (Light-Speed VCT, GE Healthcare, Milwaukee, Wisconsin, USA) with the following scanning parameters: 120 kV, 200 mA, 0.625 mm collimation, 1.5 mm increment and 3 mm reconstruction. In addition, 60–120 mL ioversol (Optiray 320 mg/mL, Tyco Healthcare, Montreal, Canada) was intravenously injected, based on the patient's body mass index (BMI) (3 mL per BMI, 20 mL if BMI < 20 and 120 mL if BMI > 40). The scan range of the chest CT was from the lower half of the neck to the adrenal glands, and both

chest CT and CXR were conducted with the patient in the supine position with both arms down.

The presence of CVC, SVC entrance and RA insertion of the CVC tip were verified in the chest CT and CXR images by using picture archiving and communications system (PACS; Marosis, Seoul, Republic of Korea). The decision was made based on the agreement of two separate researchers. On CT imaging, the identification of the CVC tip below the crista terminalis confirmed RA insertion, whereas tip location below the level of where both the brachiocephalic veins merge to form the SVC was defined as an entrance into the SVC.

A horizontal line perpendicular to the carina and CVC tip was drawn in the CXR image and on the CT scout image. Using the distance measurement function of PACS, the vertical distance of the two horizontal lines was measured and recorded as the TC distance. All TC distance measurements were undertaken by the same author. The carina level was defined as zero; the TC distance was described as a negative or positive number if the CVC tip was above or below the carina, respectively. The thoracic width was measured as the distance between the two points where the line perpendicular to the body axis at the level of the ceiling of the right diaphragm met the internal surface of the ribs (figure 1). The TC distance was measured both from CXR and the scout film of the chest CT, and the distances were compared to confirm the reliability of the CXR measurement. The TC distance was divided by the BMI (body weight (kg)/height² (m)) and by the thoracic width to obtain body size-adjusted values.

Outcomes

The primary outcome was the detection of SVC entrance and RA insertion of the CVC tip, and secondary outcomes were the reference TC distance range indicating the SVC entrance and extracardiac placement of the CVC tip and the relative predictive ability of body size-adjusted TC distance values.

Statistical analysis

Data with normal distribution are presented as mean \pm SD, and non-parametric data are presented as the median (IQR). The comparison of continuous variables was undertaken with the independent t-test or the Mann-Whitney U test for data with normal or non-normal distribution, respectively. The matched-pair analysis of TC distances measured from the CXR and chest CT images were undertaken with the Wilcoxon signed ranks test. We conducted receiver-operating characteristics (ROC) analysis to assess the predictive ability of the TC distance in the CXR images to ascertain the SVC entrance or RA insertion of the CVC tip, and the area under curve (AUC) was calculated to quantify the predictive ability. The ROC analyses were repeated with the body size-adjusted TC distance values, and their AUCs were compared with those of the TC distance values by using the DeLong test.²⁷ The cut-off point of the TC distance to detect SVC passage of

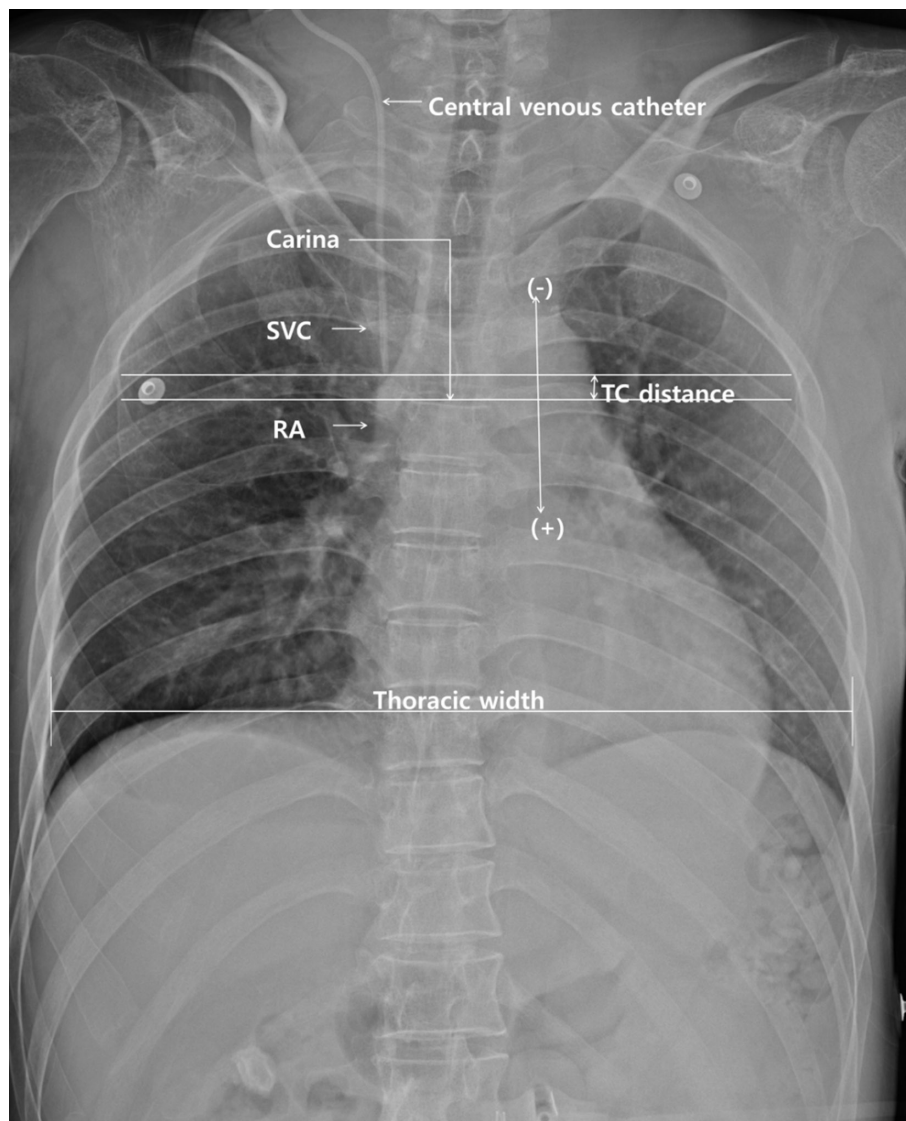


Figure 1 Definition of the tip-to-carina (TC) distance: Each horizontal line perpendicular to the carina and central venous catheter (CVC) tip was drawn on the simple chest X-ray image. The vertical distance of the two horizontal lines was measured and defined as the TC distance. The position in the carina is defined as zero, and positioning of the CVC tip above (–) or below (+) the carina is recorded. RA, right atrium; SVC, superior vena cava.

the CVC tip was defined as a value that could maximise sensitivity while maintaining 100% specificity. Similarly, the cut-off point to detect RA insertion was defined as a value that maximised specificity while maintaining 100% sensitivity. All statistical analyses were conducted in IBM SPSS Statistics V.26.0 (IBM), except for the comparison of ROC curves for which we used R V.4.0.0 (The R Foundation for Statistical Computing, <https://www.r-project.org/foundation/>). Statistical significance was set to p value <0.05 .

RESULTS

Participants' characteristics

During the study period, a total of 758 patients met the inclusion criteria, and 479 of them were included in the final analysis dataset after the exclusion of 279 patients (figure 2). The baseline data of the study participants are

described in table 1. There was no significant difference between the TC distance measured on CXR and on the scout film of the chest CT ($p=0.638$).

Ability of TC distance and body size-adjusted TC distance for detecting SVC entrance and RA insertion

The TC distance, the TC distance corrected by thoracic width and the TC distance corrected by the BMI could all significantly detect the SVC entrance of the CVC tip ($p<0.001$ for all). The AUCs of the TC distance, the TC distance corrected by thoracic width and the TC distance corrected by the BMI were 0.987, 0.989 and 0.992, respectively (figure 3A, B). There was no statistically significant difference in the comparisons of ROC curves of the TC distance with those of the TC distance corrected by the thoracic width as well as those of the TC distance corrected by the BMI ($p=0.189$ and 0.8258 , respectively). The cut-off value of the TC distance to detect the SVC

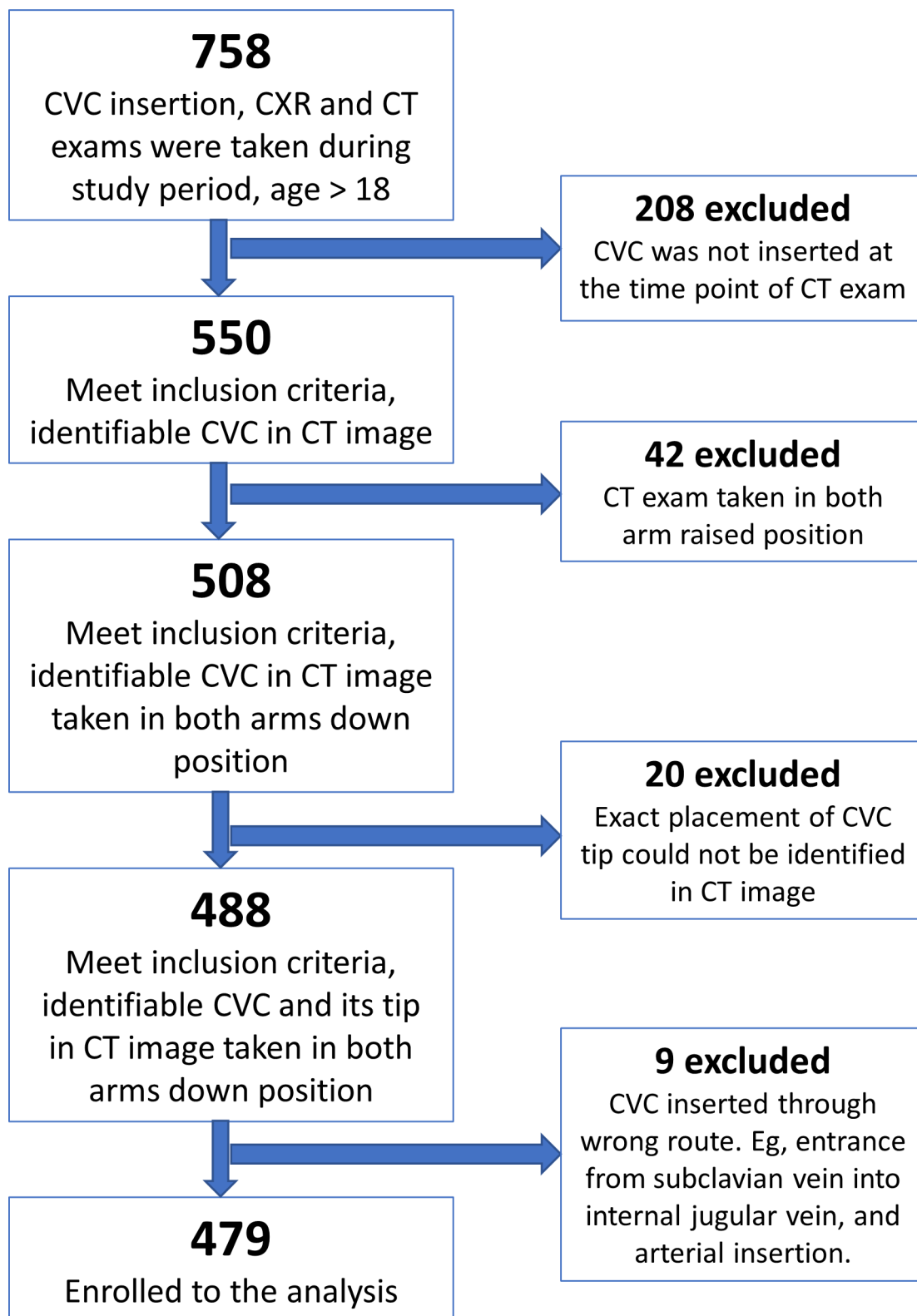


Figure 2 Flow diagram of the patient disposition in the study. CVC, central venous catheter; CXR, chest X-ray.

entrance of the CVC tip was -6.70 mm (sensitivity 89.8% and specificity 100%).

The TC distance, the TC distance corrected by the thoracic width and the TC distance corrected by the BMI could all significantly detect RA insertion of the CVC tip ($p < 0.001$ for all). The AUCs of the TC distance, the

TC distance corrected by the thoracic width and the TC distance corrected by BMI were 0.966, 0.966 and 0.947, respectively, (figure 3C, D). There was a statistically significant difference between ROC curves of the TC distance and the TC distance corrected by the BMI. However, there was no significant difference between the ROC

Table 1 Baseline characteristics of the study participants

	Total	SVC entrance		RA insertion		
		No (n=18)	Yes (n=461)	No (n=375)	Yes (n=104)	
Male sex	254	11, 4.3%	243, 95.7%	221, 87.0%	33, 13.0%	
Age	73 (58–80)	74.5 (55–78)	73 (58–80)	74 (61–81)	69 (52–77.5)	
Height	161 (155–168)	157 (151–159)	162 (155–168)	162 (155–170)	159.5 (155–165.8)	
Weight	56.0 (48.7–67.5)	58.5 (47.6–66.8)	56.0 (48.7–68.0)	55.7 (48.0–66.4)	57.1 (50.9–70.4)	
BMI	21.4 (18.8–25.2)	24.6 (19.0–28.4)	21.3 (18.8–25.0)	21.1 (18.5–24.9)	22.9 (19.6–26.8)	
Access	IJV	101	10, 9.9%	91, 90.1%	93, 92.1%	8, 7.9%
	SCV	378	8, 2.1%	370, 97.9%	282, 74.6%	96, 25.4%
Thoracic width	288.7±22.4	289.6±21.9	288.6±22.4	290.3±22.3	282.8±21.6	
TC distance, CXR*	18.6 (4.2–32.6)	−49.9 (−53.3 to −28.7)	20.0 (6.4–34.8)	11.6 (−0.7 to 23.9)	47.0 (38.4–60.8)	
TC distance, scout†	18.6 (4.6–33.5)	−39.9 (−56.3 to −29.7)	20.0 (6.6–34.6)	11.5 (0.3–23.9)	47.5 (38.7–60.3)	

Unit of the measurements: male sex (n, %), age (years), height (cm), weight (kg), access (n, %), thoracic width (mm) and TC distance (mm). Numerical values are described as median (IQR), except for male sex (n, %), access (n, %) and thoracic width (mean±SD).

*TC distance measured on the simple chest X-ray.

†TC distance measured on the scout film of the chest CT.

BMI, body mass index; CXR, chest X-ray; IJV, internal jugular vein; RA, right atrium; SCV, subclavian vein; SVC, superior vena cava; TC, tip-to-carina.

curves of the TC distance and the TC distance corrected by the thoracic width ($p=0.995$ and 0.001 , respectively). The cut-off value of the TC distance to detect the RA insertion of the CVC tip was 15.62mm (sensitivity 100% and specificity 58.93%).

DISCUSSION

The results of the present study showed that the TC distance on the CXR is a useful parameter to confirm the appropriate positioning of the CVC tip, not only to prevent intracardiac placement that can cause serious complications but also to ensure SVC placement for accurate CVP monitoring. Furthermore, we ascertained the optimal reference range of the TC distance based on the results.

Previous studies of methods to confirm the location of CVC tip, including those that evaluated the TC distance on simple CXR, were undertaken to only assess the ability of imaging to avoid intracardiac placement of the CVC tip.^{9–12 17–24 28–31} The results of this study confirmed that the TC distance in the CXR could confirm not only extracardiac placement but also the SVC entrance of the CVC tip. The confirmation of intra-SVC placement of CVC tip is a prerequisite for accurate CVP monitoring, which is a crucial factor when considering the purpose of such an invasive procedure.

The results of recent clinical trials suggest that CVP may not be a reliable index for assessing fluid responsiveness, and the use of CVP for such a purpose is not recommended in the most of clinical guidelines any more, despite its widespread utilisation.^{32 33} Moreover, intracardiac placement of CVC is not that dangerous as was before, owing to the development of the material.³⁴ These facts may devalue the precise confirmation of

CVC tip placement. However, CVP measurement still has some valuable aspects, and, most of all, it is still the most frequently used haemodynamic variable for deciding when to start fluid administration during critical care.³⁵ Furthermore, it may be unethical to take an unnecessary risk even if it is minimal. Hence, the positioning of CVC tip in an appropriate place is still important as long as CVP insertion is performed.

The body size-adjusted TC distance showed similar or even a significantly inferior ability to detect the SVC entrance and RA insertion of the CVC tip than the unadjusted TC distance in the present dataset. This result indicates that the body size adjustment of the TC distance to confirm appropriate positioning of the CVC tip is not necessary.

We specified cut-off values to confirm the SVC insertion of the CVC tip as the value with maximal sensitivity and a specificity of 100%. Similarly, we specified the cut-off value for intracardiac insertion of the CVC tip as a value with maximal specificity and a sensitivity of 100%. These cutoffs were defined on the premise that it was more important to prevent false-positive than false-negative results for the determination of SVC entrance. Otherwise, the prevention of false negative is more important than that of false positive in the determination of intracardiac placement, with due consideration of their purposes. Thus, we obtained a range of TC distance (−6.69 to 15.61 mm) that could assure both SVC insertion and extracardiac placement of CVC tip. One may think that the cut-off value to detect intracardiac insertion can cause critical error in practice, because significantly high false-positive rate is expected. However, what we have to do in the case that TC distance exceed the cut-off value indicating intracardiac insertion is just a simple moving

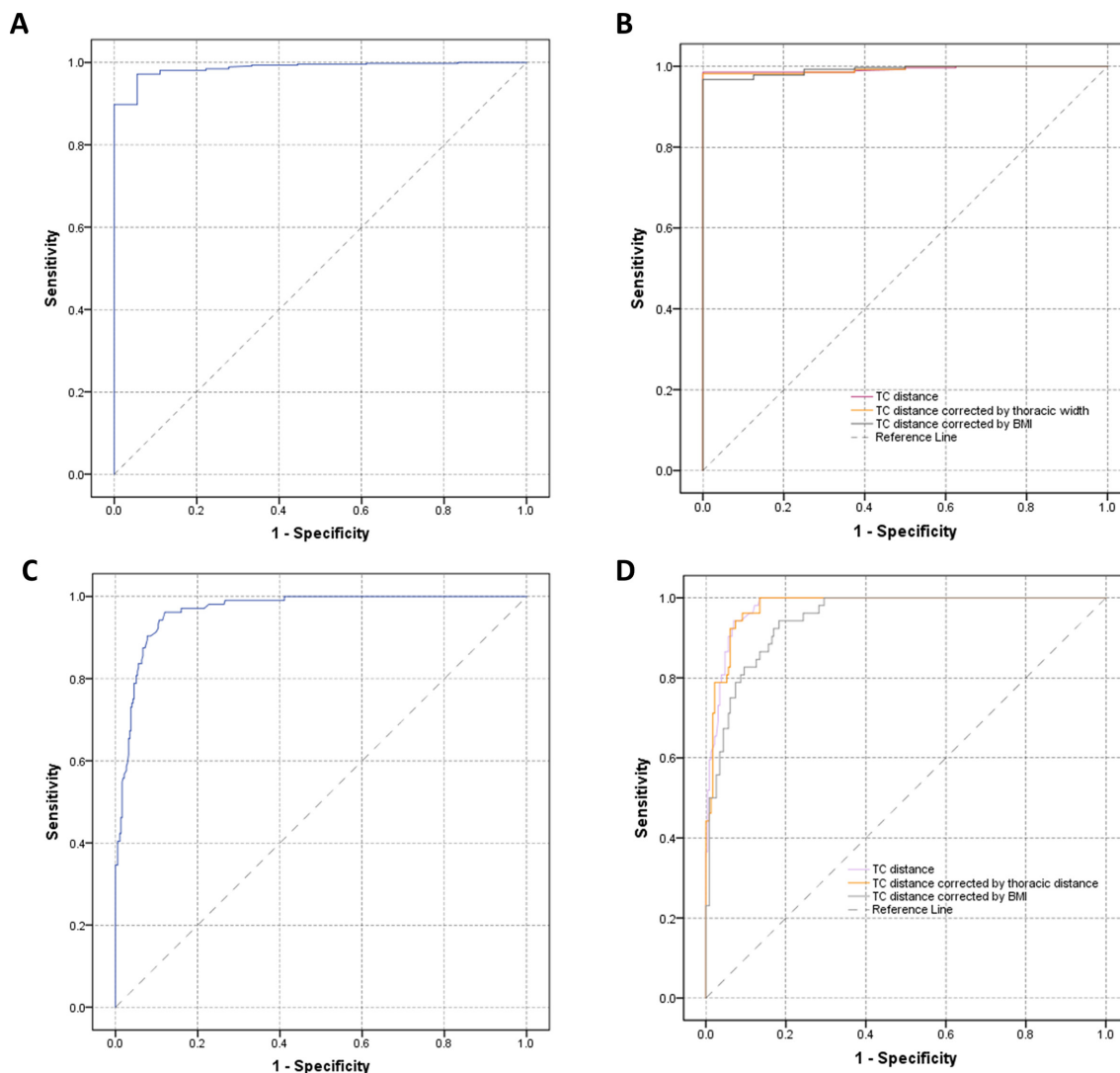


Figure 3 Receiver operating characteristics (ROC) curves of the tip-to-carina (TC) distance and the body size-adjusted TC distance. (A) ROC curve of the TC distance to detect the passage of the central venous catheter (CVC) tip into the superior vena cava (SVC). (B) Comparison of the ROC curves of the TC distance and the body size-adjusted TC distance to detect the SVC passage of the CVC tip. (C) ROC curve of the TC distance to detect the entrance of the CVC tip into the right atrium (RA). (D) The comparison of the ROC curves of the TC distance and the body size-adjusted TC distance to detect the RA entrance of the CVC tip. BMI, body mass index.

backward of CVC tip within the suggested range of TC distance. Hence, the proper positioning of CVC tip can be easily maintained even in the case of false detection of intracardiac insertion. This range also confirms the results of previous studies that suggested the carina as an anatomical landmark for the determination of CVC tip positioning based on anatomical analyses of cadavers or chest MRI/CT scan, given that the carina is definitely included in the cut-off range.^{17 22} The carina in the CXR can be considered to be a simpler landmark, based on the results of both the present and the previous studies, and we can ascertain safe and precise positioning of the CVC tip if the tip is located within the range of the TC distance between -6.69 mm and 15.61 mm.

A recent study by Dulce *et al*³⁰ that analysed the topographic relationships of the extrapericardial SVC by using CXR and CT imaging suggested that a location 9

mm above the carina (TC distance -9 mm) was the appropriate position for CVC tip placement, which is quite different from that of our results. We excluded the data on individuals whose chest CT images were obtained with both arms raised. However, the study of Dulce *et al* mostly used the data of participants whose CT images were obtained with both arms raised. This prominent discordance may be attributable to the differences in arm position during the chest CT scan examination, considering that the position of the CVC tip can change when both the arms are raised.²⁶ The range of the TC distance determined from the present analysis could be more reliable as a reference range for the TC distance on CXR images, because the CXR is obtained with both arms downward in almost every condition.

The present study has some limitations. First, our study was a retrospective analysis of the dataset from a single

centre, and there may be a potential bias in our results due to the incompleteness of our dataset (especially with regard to the body-size parameters) or a possible bias in the characteristics of the study participants. Therefore, the generalisation of the results of this study needs to be cautiously undertaken. Second, the actual CVC tip position could be different at the time point of CXR and chest CT imaging, because of the maximum 24-hour interval between the CXR and chest CT examinations. However, the result of paired comparison of CT distances measured from both CXR and chest CT imaging in the present dataset revealed that the influence of this factor was minimal. Nevertheless, there could still be a chance of significant CVC tip migration, considering that even the respiratory phases could affect CVC tip position.³⁶ Third, we excluded some cases during data collection because of the difficulty in ascertaining the position of the CVC tip on a chest CT image, and this could cause a selection bias although we made every effort not to exclude a case intentionally. The exclusion was carefully decided only when two independent researchers agreed that CVC tip was unidentifiable due to poor image quality or being obscured by contrast media.

CONCLUSIONS

The TC distance in CXR is a simple and precise method to confirm not only the safe placement of the CVC tip but also its optimal positioning for accurate haemodynamic monitoring. The TC distances in the range of -6.69 mm to 15.61 mm can be used as a reference range to define cutoffs for the optimal positioning of the CVC tip.

Correction notice The article has been corrected since it was published. Contributed equally statement has been added for this article.

Contributors Conceptualisation, formal analysis, methodology and writing—review and editing: TNC; data curation: SM; funding acquisition: JB; investigation: MK, JB and SM; visualisation: MK and writing—original draft: MK and JB.

Funding This work was supported by the Basic Science Research Program through the National Research Foundation of Korea (NRF) funded by the Ministry of Science and ICT (NRF-2018R1C1B504467113) to JB.

Competing interests None declared.

Patient and public involvement Patients and/or the public were not involved in the design, or conduct, or reporting, or dissemination plans of this research.

Patient consent for publication Not required.

Ethics approval The protocol for this retrospective observational study was reviewed and approved by the Institutional Ethics Committee (ethical committee of CHA University, CHA Bundang Medical Center, approval no. 2019-11-068). The ethical body waived the need for written informed consent, and approved anonymised data collection through chart reviews in the electronic medical record (EMR) system.

Provenance and peer review Not commissioned; externally peer reviewed.

Data availability statement Data are available in a public, open access repository (10.6084/m9.figshare.12403445).

Open access This is an open access article distributed in accordance with the Creative Commons Attribution Non Commercial (CC BY-NC 4.0) license, which permits others to distribute, remix, adapt, build upon this work non-commercially, and license their derivative works on different terms, provided the original work is properly cited, appropriate credit is given, any changes made indicated, and the use is non-commercial. See: <http://creativecommons.org/licenses/by-nc/4.0/>.

ORCID iD

Tae Nyoung Chung <http://orcid.org/0000-0003-3537-4136>

REFERENCES

- Ganeshan A, Warakaulle DR, Uberoi R. Central venous access. *Cardiovasc Intervent Radiol* 2007;30:26–33.
- Cecconi M, Hofer C, Teboul J-L, et al. Fluid challenges in intensive care: the FENICE study: a global inception cohort study. *Intensive Care Med* 2015;41:1529–37.
- Guyton AC, Jones CE. Central venous pressure: physiological significance and clinical implications. *Am Heart J* 1973;86:431–7.
- Booth SA, Norton B, Mulvey DA. Central venous catheterization and fatal cardiac tamponade. *Br J Anaesth* 2001;87:298–302.
- Collier PE, Blocker SH, Graff DM, et al. Cardiac tamponade from central venous catheters. *Am J Surg* 1998;176:212–4.
- McGee DC, Gould MK. Preventing complications of central venous catheterization. *N Engl J Med* 2003;348:1123–33.
- Merrer J, De Jonghe B, Golliot F, et al. Complications of femoral and subclavian venous catheterization in critically ill patients: a randomized controlled trial. *JAMA* 2001;286:700–7.
- NAVAN. Tip location of peripherally inserted central catheters. *Journal of Vascular Access Devices* 1998;3:8–10.
- Hsu J-H, Wang C-K, Hung C-W, et al. Transesophageal echocardiography and laryngeal mask airway for placement of permanent central venous catheter in cancer patients with radiographically unidentifiable SVC-RA junction: effectiveness and safety. *Kaohsiung J Med Sci* 2007;23:435–41.
- Jeon Y, Ryu H-G, Yoon S-Z, et al. Transesophageal echocardiographic evaluation of ECG-guided central venous catheter placement. *Can J Anaesth* 2006;53:978–83.
- Reynolds N, McCulloch AS, Pennington CR, et al. Assessment of distal tip position of long-term central venous feeding catheters using transesophageal echocardiography. *JPEN J Parenter Enteral Nutr* 2001;25:39–41.
- Wirsing M, Schummer C, Neumann R, et al. Is traditional reading of the bedside chest radiograph appropriate to detect intraatrial central venous catheter position? *Chest* 2008;134:527–33.
- Kim S-C, Heinze I, Schmiedel A, et al. Ultrasound confirmation of central venous catheter position via a right supraclavicular fossa view using a microconvex probe: an observational pilot study. *Eur J Anaesthesiol* 2015;32:29–36.
- Kosaka M, Oyama Y, Uchino T, et al. Ultrasound-Guided central venous tip confirmation via right external jugular vein using a right supraclavicular fossa view. *J Vasc Access* 2019;20:19–23.
- Smit JM, Raadsen R, Blans MJ, et al. Bedside ultrasound to detect central venous catheter misplacement and associated iatrogenic complications: a systematic review and meta-analysis. *Crit Care* 2018;22:65.
- Ablordepey EA, Drewry AM, Theodoro DL, et al. Current practices in central venous catheter position confirmation by point of care ultrasound: a survey of early Adopters. *Shock* 2019;51:613–8.
- Albrecht K, Nave H, Breitmeier D, et al. Applied anatomy of the superior vena cava—the carina as a landmark to guide central venous catheter placement. *Br J Anaesth* 2004;92:75–7.
- Chalkiadis GA, Goucke CR. Depth of central venous catheter insertion in adults: an audit and assessment of a technique to improve tip position. *Anaesth Intensive Care* 1998;26:61–6.
- Lee JB, Lee YM. Pre-measured length using landmarks on posteroanterior chest radiographs for placement of the tip of a central venous catheter in the superior vena cava. *J Int Med Res* 2010;38:134–41.
- McGee WT, Ackerman BL, Rouben LR, et al. Accurate placement of central venous catheters: a prospective, randomized, multicenter trial. *Crit Care Med* 1993;21:1118–23.
- Rutherford JS, Merry AF, Occleshaw CJ. Depth of central venous catheterization: an audit of practice in a cardiac surgical unit. *Anaesth Intensive Care* 1994;22:267–71.
- Schuster M, Nave H, Piepenbrock S, et al. The carina as a landmark in central venous catheter placement. *Br J Anaesth* 2000;85:192–4.
- Stonelake PA, Bodenham AR. The carina as a radiological landmark for central venous catheter tip position. *Br J Anaesth* 2006;96:335–40.
- Aslmy Z, Dewald CL, Heffner JE. MRI of central venous anatomy: implications for central venous catheter insertion. *Chest* 1998;114:820–6.
- Sonavane SK, Milner DM, Singh SP, et al. Comprehensive imaging review of the superior vena cava. *Radiographics* 2015;35:1873–92.
- Ouriel K, Brennan JK, Desch C, et al. Migration of a permanent central venous catheter. *JPEN J Parenter Enteral Nutr* 1983;7:410–1.



- 27 DeLong ER, DeLong DM, Clarke-Pearson DL. Comparing the areas under two or more correlated receiver operating characteristic curves: a nonparametric approach. *Biometrics* 1988;44:837–45.
- 28 Andropoulos DB, Stayer SA, Bent ST, *et al.* A controlled study of transesophageal echocardiography to guide central venous catheter placement in congenital heart surgery patients. *Anesth Analg* 1999;89:65–70.
- 29 Caruso LJ, Gravenstein N, Layon AJ, *et al.* A better landmark for positioning a central venous catheter. *J Clin Monit Comput* 2002;17:331–4.
- 30 Dulce M, Steffen IG, Preuss A, *et al.* Topographic analysis and evaluation of anatomical landmarks for placement of central venous catheters based on conventional chest X-ray and computed tomography. *Br J Anaesth* 2014;112:265–71.
- 31 Reeves ST, Bevis LA, Bailey BN. Positioning a right atrial air aspiration catheter using transesophageal echocardiography. *J Neurosurg Anesthesiol* 1996;8:123–5.
- 32 Cecconi M, De Backer D, Antonelli M, *et al.* Consensus on circulatory shock and hemodynamic monitoring. Task force of the European Society of intensive care medicine. *Intensive Care Med* 2014;40:1795–815.
- 33 Marik PE, Cavallazzi R. Does the central venous pressure predict fluid responsiveness? An updated meta-analysis and a plea for some common sense. *Crit Care Med* 2013;41:1774–81.
- 34 Pittiruti M, Lamperti M. Late cardiac tamponade in adults secondary to tip position in the right atrium: an urban legend? A systematic review of the literature. *J Cardiothorac Vasc Anesth* 2015;29:491–5.
- 35 Monge García MI, Santos Oviedo A. Why should we continue measuring central venous pressure? *Med Intensiva* 2017;41:483–6.
- 36 Pan PP, Engstrom BI, Lungren MP, *et al.* Impact of phase of respiration on central venous catheter tip position. *J Vasc Access* 2013;14:383–7.