

BMJ Open Protocol for the VAL-MAP 2.0 trial: a multicentre, single-arm, phase III trial to evaluate the effectiveness of virtual-assisted lung mapping by bronchoscopic dye injection and microcoil implementation in patients with small pulmonary nodules in Japan

Keiko Ueda,¹ Yukari Uemura,² Masaaki Sato³

To cite: Ueda K, Uemura Y, Sato M. Protocol for the VAL-MAP 2.0 trial: a multicentre, single-arm, phase III trial to evaluate the effectiveness of virtual-assisted lung mapping by bronchoscopic dye injection and microcoil implementation in patients with small pulmonary nodules in Japan. *BMJ Open* 2019;**9**:e028018. doi:10.1136/bmjopen-2018-028018

► Prepublication history and additional material for this paper are available online. To view these files, please visit the journal online (<http://dx.doi.org/10.1136/bmjopen-2018-028018>).

Received 24 November 2018
Revised 20 July 2019
Accepted 12 August 2019



© Author(s) (or their employer(s)) 2019. Re-use permitted under CC BY-NC. No commercial re-use. See rights and permissions. Published by BMJ.

For numbered affiliations see end of article.

Correspondence to

Dr Masaaki Sato;
satom-sur@h.u-tokyo.ac.jp

ABSTRACT

Introduction Tumour localisation is important for successful resection of lung nodules with optimal resection margins in sublobar resection. Virtual-assisted bronchoscopic localisation technique combined with dye marking and microcoil placement (VAL-MAP 2.0) is a minimally invasive, virtual-assisted, bronchoscopic technique that combines dye marking and microcoil implementation. As indwelling microcoils can provide information on the depth from the lung surface, they can be applied for deeply located small lung tumours that are barely identifiable by surface dye marking. This proposed study will examine the effectiveness of VAL-MAP 2.0 in patients with small pulmonary nodules.

Methods and analysis This is a multicentre, prospective, single-arm, clinical trial. A total of 65 patients will be registered to undergo VAL-MAP 2.0 followed by thoracoscopic surgery. The primary outcome is successful resection, defined as resection of the lesion with optimal resection margins. The goal of the study is the achievement of a successful resection rate of 80%.

Ethics and dissemination The study was approved by the Clinical Research Review Boards of the University of Tokyo (approval number 218 003SP) for all institutes, and the Technical Review Board for Advanced Medicine Category B of the Ministry of Health, Labour and Welfare. Results of the primary and secondary endpoints will be submitted for publication in a peer-reviewed journal.

Trial registration number jRCTs031180099

INTRODUCTION

Lung cancer remains the leading cause of cancer death worldwide. The 5-year survival rate of patients with lung cancer is lower than that of patients with other malignant tumours.¹ However, the survival statistics after surgical treatment in patients with early-stage (stage 1a) lung cancer are considerably good compared with those for patients

Strengths and limitations of this study

- This is the first clinical trial to investigate the effectiveness and safety of a virtual-assisted bronchoscopic localisation technique combined with dye marking and microcoil placement (VAL-MAP 2.0) as a guide for thoracoscopic sublobar lung resection.
- The results of this clinical trial will provide physicians with important information regarding the use of VAL-MAP 2.0 for intraoperative tumour localisation to enable accurate resection with sufficient margins, even for small, deeply located, early-stage lung tumours.
- An advantage of this trial is that there is expected to be little technical variability among physicians, as the technique per se is relatively simple, and most of the physicians participated in the prior multicentre trial for dye marking, which is technically similar to VAL-MAP 2.0.
- The limitations are biases in patient selection and outcome evaluation due to the single-arm design, despite the use of strict eligibility criteria and an objective endpoint.

with progressive, inoperable, lung cancer requiring vigorous radiotherapy or chemotherapy. Thus, early detection and complete surgical resection are key factors in reducing mortality in patients with lung cancer.^{1,2}

One surgical intervention option for early-stage lung cancer is sublobar lung resection, such as wedge resection or segmentectomy. The advantage of sublobar resection is that it reduces the size of total lung resection; however, intraoperative nodule localisation for the determination of optimal resection lines is often challenging, especially in barely palpable small nodules. To aid in tumour

localisation, several lung marking techniques have been proposed.^{3–10} However, inaccurate marking of operational sites may result in conversion from wedge resection to a larger resection, such as lobectomy, and may also lead to local recurrence due to a malignant positive margin.^{11–15}

Sublobar lung resection is also applied in the treatment of metastatic lung tumours, such as those derived from colon cancer. In such cases, the same principles apply as for primary lung cancer regarding the importance of complete resection, associated locoregional recurrence and the impact of these factors on patient survival. An appropriate tumour localisation technique also plays an important role in achieving complete resection of small and deeply located metastatic lung tumours.

Several preoperative lung marking methods have been performed to enable tumour identification, particularly for relatively deep tumours, including the placement of a hookwire and metallic coil via the CT-guided needle-mediated approach. Clinical trials have shown that microcoil localisation contributes to the successful identification of small pulmonary nodules.^{3–5} However, a CT-guided needle-mediated approach results in pneumothorax or even potentially fatal air embolism in 1%–2% of patients.^{6–9}

To overcome the safety concerns associated with needle puncture, bronchoscopic virtual-assisted lung mapping (VAL-MAP) was developed by Sato *et al* in 2012.¹⁵ In VAL-MAP, multispot dye markings are made under the guidance of virtual bronchoscopic images to provide geometric information (a ‘lung map’).¹⁰ This lung map provides intraoperative assistance for the localisation of barely palpable lung nodules and can help surgeons to determine optimal resection lines for sublobar resection.¹⁰ A multicentre, clinical trial in Japan showed that VAL-MAP has a high degree of accuracy in mapping, achieves a successful resection rate of 87.7% (defined as tumour resection with adequate surgical margins) and has a satisfactory safety profile with only one serious case of subcutaneous emphysema.^{16 17} However, this previous study also revealed that the acquisition of resection margins for deeply located lung nodules is a limitation of VAL-MAP; multivariate analysis revealed that the most significant risk factor for resection failure was the presence of tumours with a required resection line depth of more than 30 mm from the pleural surface.¹⁷ These findings indicate that it is critical to obtain accurate information on tumour depth and deep resection lines to ensure the success of sublobar lung resection.

To counter these limitations in the performance of VAL-MAP for deeply located lung nodules, we have developed a new VAL-MAP technology using a combination of bronchoscopic multispot dye markings and microcoil placements (VAL-MAP 2.0). Tumour depth is measured by the observation of indwelling microcoil positions on intraoperative fluoroscopy, and this enables improved determination of the optimal resection lines compared with the previous method that relied only on the subjective ‘sense’ of the surgeon about the appropriate depth

of the resection line. In addition, the minimally invasive bronchoscopic approach for microcoil implementation in VAL-MAP 2.0 is relatively safe compared with the conventional CT-guided needle puncture approach. A pilot study showed that VAL-MAP 2.0 contributed to the localisation of deep nodules in all six cases (seven lesions) without any adverse events (AEs).¹⁸ However, the operational settings of this previous clinical trial did not permit the application of randomisation and blinding.¹⁸ Randomisation for patients with deeply located tumours to undergo either VAL-MAP 2.0 or the CT-guided needle-mediated approach is not possible because in the current clinical setting in Japan each physician’s choice of operational approach is based on the technical differences between the two approaches, making it difficult for a physician to be forced to perform the other approach in a randomised clinical trial. In addition, most physicians try to avoid the invasive CT-guided needle-mediated approach due to safety reasons. Therefore, a larger-scale, well-designed, single-arm trial is needed to establish the effectiveness and safety of VAL-MAP 2.0, as represented by a satisfactory rate of successful resection.

The aim of the single-arm, multicentre, phase III clinical trial described in the present manuscript is to examine the effectiveness of VAL-MAP 2.0 in obtaining optimal surgical margins in sublobar lung resection for deeply located small lung tumours.

METHODS AND ANALYSIS

Study objectives

This trial aims to investigate the effectiveness of VAL-MAP 2.0 using metallic microcoils combined with a multispot dye-marking technique in obtaining sufficient surgical margins in sublobar lung resection.

Trial design

This multicentre, prospective, single-arm, clinical trial will be conducted from 1 February 2019 to 31 March 2020 under the supervision of the Ministry of Health, Labour and Welfare in Japan. Eight hospitals have been registered as study sites. The study protocol was issued on 18 September 2018 and the amendment number is 1.1.

A total of 65 patients who require sublobar lung resection will undergo VAL-MAP 2.0 for lung tumour identification after giving informed consent. The dates for participant recruitment will be from the time of ethical approval until 01 March 2020. The primary outcome is successful resection, defined as resection of the lesion with sufficient margins. The goal of the study is the achievement of a successful resection rate of 80%.

Patient and public involvement

Patients and/or the public were not involved in developing the research questions, patient recruitment and/or the conduct of the study. The results will contribute to better outcomes for patients with lung tumours.

Sample selection

Inclusion criteria

- (1) Patients with suspected/diagnosed pulmonary malignancy who require the establishment of resection lines other than the typical interlobar fissure.
- (2) A tumour that is expected to be barely identifiable intraoperatively, and will, thus, need particularly accurate demarcation for visualisation (indications for dye injection).
 - i. Due to the characteristics of the lesion, including any of the following:
 - a. Lesions wholly or partially composed of ground-glass opacity.
 - b. Lesions with a tumour diameter of 5 mm or less.
 - c. Lesions with a distance from the visceral pleura that is larger than the tumour diameter.
 - ii. Due to the underlying lung conditions, including any of the following:
 - a. Severe advanced pleural adhesion (eg, history of open chest surgery).
 - b. Pre-existing benign nodules that are confusing and misleading.
- (3) A tumour that is expected to be barely identifiable intraoperatively with dye injection alone, and is, therefore, expected to require the introduction of a microcoil, including any one of the following conditions:
 - i. Lesions indicated for wedge resection, with the margin on the central side expected to be barely determinable without microcoil application; that is, the resection line will be inside the one-third of the outer line, but the tumour centre is located outside the one-third of the external line on CT images.
 - ii. Lesions indicated for sublobar resection (wedge resection or segmentectomy), with the margin on the central side expected to be barely determinable without microcoil application; that is, the tumour centre is located inside the one-third of the external line on CT images.
 - iii. Anticipation of a substantial degree of lung pigmentation (eg, pneumoconiosis, emphysema or fibrosis).
- (4) The patient has provided informed consent.

Exclusion criteria

1. Allergy to platina or indigo carmine
2. Microcoil insertion is expected to be difficult due to conditions, such as anatomical deformity, distortion, disappearance of a bronchus due to previous surgery or congenital abnormality (bronchial atresia or bronchial occlusion), or post-inflammatory bronchiectasis (bronchial dilation).
3. Pregnancy.
4. Difficulty in obtaining informed consent (eg, patient is unconscious or less than 20 years old).
5. Bronchoscopy and/or mapping cannot be conducted due to existing complications.
6. Operational difficulty due to anatomical reasons (eg, a tumour for which sublobar lung resection cannot

possibly acquire sufficient resection margins due to the location of the lesion and/or the surgical plan).

Study procedure

Registration

An electronic data capture system (Viedoc, Pharma Consulting Group, Tokyo, Japan) will be used for central registration using an identification code. We will perform both primary and secondary registration. The eligibility assessment committee will confirm the study eligibility of each patient at the time of primary registration to ensure homogeneity among facilities.

For the primary registration, the eligibility will be assessed based on the clinical information from CT imaging (anatomical position, maximum diameter, depth and properties of the lesion) and the percentage of ground glass-opacity (measured based on the *Lung cancer handling regulations, version 8*).¹⁹ Once the primary registration is completed, a member of the eligibility assessment committee will access the clinical information entered in the electronic data capture system. An independent member of this committee who belongs to an institute separate to the one in which the patient is being treated will judge whether there is any deviation from the eligibility criteria. After confirming that all inclusion and exclusion criteria are met, and that the eligibility assessment committee is satisfied that the patient qualifies for study inclusion, the secondary registration will be carried out (figure 1).

Planning of VAL-MAP

Lung mapping will be designed by the surgical team of each institute to achieve tumour identification and/or indication of the resection lines in wedge resection or segmentectomy. The multiple spots on the lung surface will be visualised on CT images and corresponding virtual bronchoscopy, and the target bronchi will be identified. Workstations and software, such as SYNAPSE VINCENT (Fujifilm Medical, Tokyo, Japan), will be used to generate virtual bronchoscopic and/or three-dimensional (3-D) CT images.

VAL-MAP procedure

After planning the lung map using virtual bronchoscopy, actual bronchoscopy will be conducted with sedation and local anaesthesia on the day of the operation or 1 day preoperatively. The multiple dye injection technique comprises the insertion of a metal blunt-tip catheter (PW-6C-1; Olympus, Tokyo, Japan) preloaded with 1 mL of indigo carmine (Daiichi-Sankyo, Tokyo, Japan) through the working channel of the bronchoscope (BF260F or BF-P260F; Olympus, Tokyo, Japan) into the predetermined target bronchus, using the virtual bronchoscopy images for guidance. Indigo carmine will then be gently injected under fluoroscopic confirmation. This manoeuvre will be repeated for all target bronchi.

Microcoil placement

After conducting conventional VAL-MAP with indigo carmine, a platinum C-stopper microcoil (final diameter

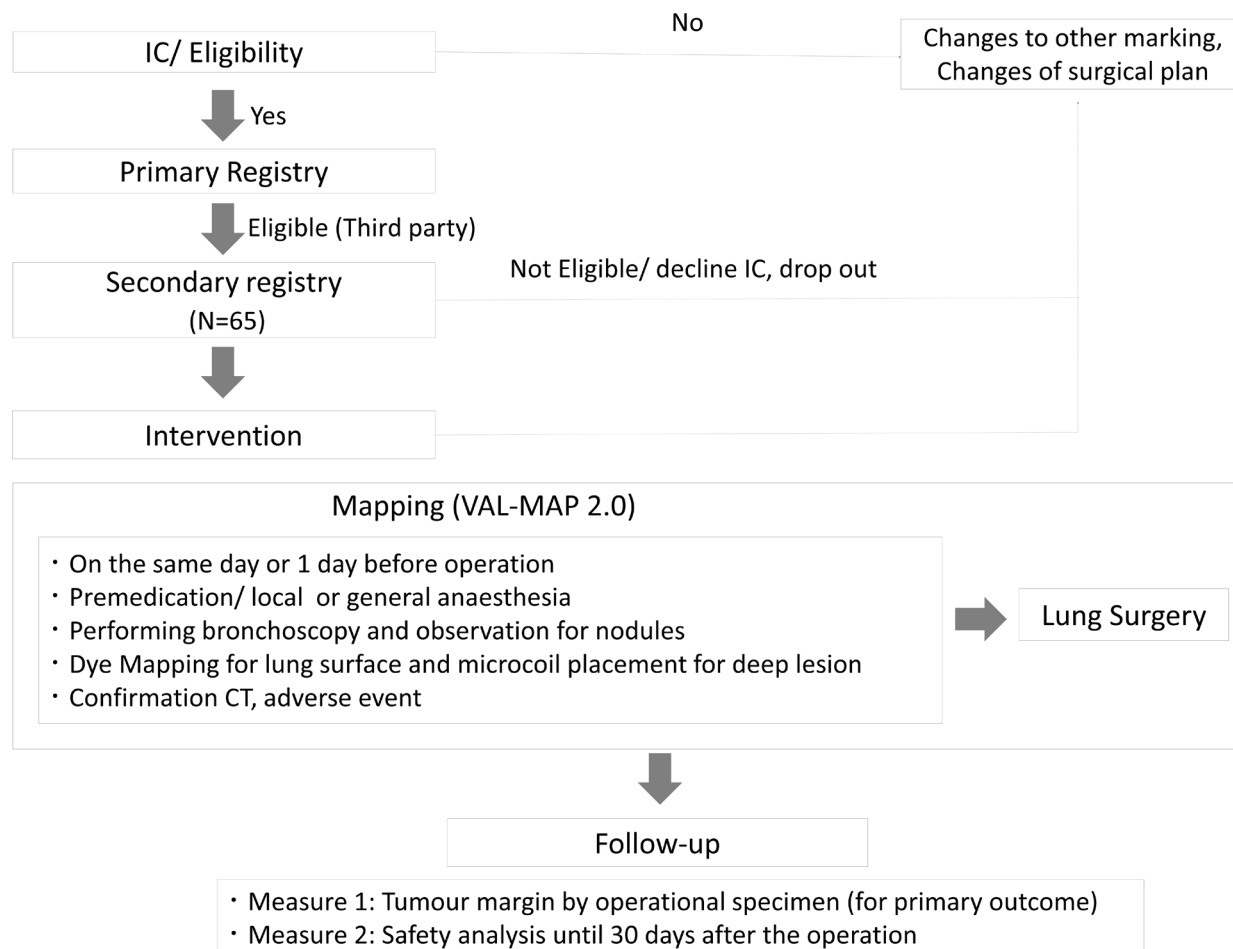


Figure 1 Flow chart of the study design. IC, inclusion criteria; VAL-MAP 2.0, virtual-assisted bronchoscopic localisation technique combined with dye marking and microcoil placement.

5 mm; Japan Piolax Medical Device, Tokyo, Japan) will be placed through a microcatheter and a pusher. When the tip of the coil-feeding catheter reaches its target point, a fibered platinum microcoil will be instilled into the target bronchus. In wedge resection, if a single bronchus reaches the lesion, a microcoil will be placed proximal to the tumour to indicate the deep resection margin. In wedge resection, if no bronchus directly reaches the lesion, multiple bronchi reaching close to the tumour will be selected for microcoil placement to indicate the deep resection margin. In segmentectomy, although the deepest resection margin is the hilum, more consideration is given to the intersegmental plane, which tends to be close to the tumour; thus, to secure the resection margins, a microcoil or microcoils will be placed to indicate the intrapulmonary intersegmental plane. The procedure is completed after fluoroscopic confirmation of the location of the metallic microcoil marker.

Post-bronchoscopic procedure and surgery

After completing the bronchoscopic procedure, a CT scan will be performed to confirm the locations of the markings; this will be done no more than 2 hours after the mapping procedure. Although indigo carmine is not radiopaque, the water density and the associated bronchial

dilation are usually visible on CT. The post-VAL-MAP CT images will be reconstructed into 3-D images for final surgical planning. The operation will be conducted using the 3-D images as references on the same day or the next day after the bronchoscopic lung mapping procedure.

Surgery will be performed under thoracoscopy, following a similar procedure to conventional VAL-MAP-assisted surgery. A tentative resection line will be determined based on the dye marks on the lung surface, using either ring forceps or a stapler. Fluoroscopy will be used to examine the relationship between the location of the microcoil and the planned resection line, and the staple line will be adjusted if necessary. After resection, the resection margin (including the staple line) will be macroscopically measured.

Postoperative follow-up

Postoperative care and follow-up will be performed in accordance with the conventional medical practice at each institution. Complications that occur during the first 30 days postoperatively will be recorded.

Outcome measures

The following assessments will be done in accordance with the study schedule.

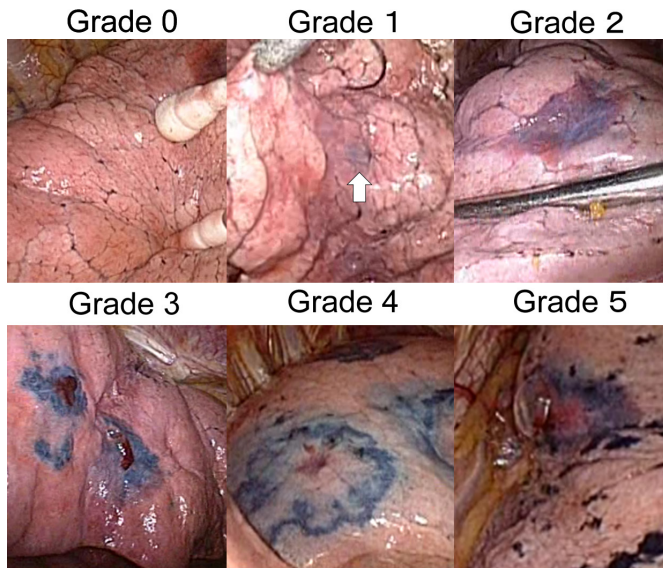


Figure 2 Bronchoscopic marking using microcoils. Bronchoscopic microcoil placement in a 65-year-old woman under fluoroscopy. An arrow with 'platinum microcoil (C-stopper)' indicates microcoils released into the bronchi. Grading of indigo carmine marking: grade 0, unidentifiable; grade 1, identifiable but faint and barely visible; grade 2, easily identifiable without a central red spot; grade 3, easily identifiable with a central red spot; grade 4, target-like appearance with or without a central red spot; and grade 5, bulla formation. This figure was reproduced from Sato *et al*²⁰ after the attainment of appropriate permission.

Resection margins will be measured macroscopically by the surgeon intraoperatively while the lung is deflated. The lesion diameter that was measured on preoperative CT will be used to calculate the resection margins. If the resected lesion cannot be identified macroscopically but is detected on microscopic or pathological examination, the lesion will be considered successfully resected; the margins will then be measured at the pathology department, taking the width of the stapler into account.

The quality of each dye-mark will be graded using the system described previously²⁰ (figure 2), and the presence/absence and position of the microcoils will be recorded (figure 3). Microcoil placements will be defined as misaligned when post-mapping CT shows that the inserted position is located 5 mm or more from the planned position.

The planned/practiced operation types will be recorded as wedge resection, including simple segmentectomy (ie, conventional anatomical segmentectomy), or extended segmentectomy that extends beyond the anatomical segment into an adjacent segment. The planned/practiced surgical approach will be recorded as thoracoscopic surgery, thoracoscopically assisted small thoracotomy, or thoracotomy.

The contribution of lung mapping to the operation will be graded by the surgeons as follows: grade A, the same level of operative precision was judged to be impossible without localisation; grade B, a similar level of precision was judged to be possible, but localisation enabled the

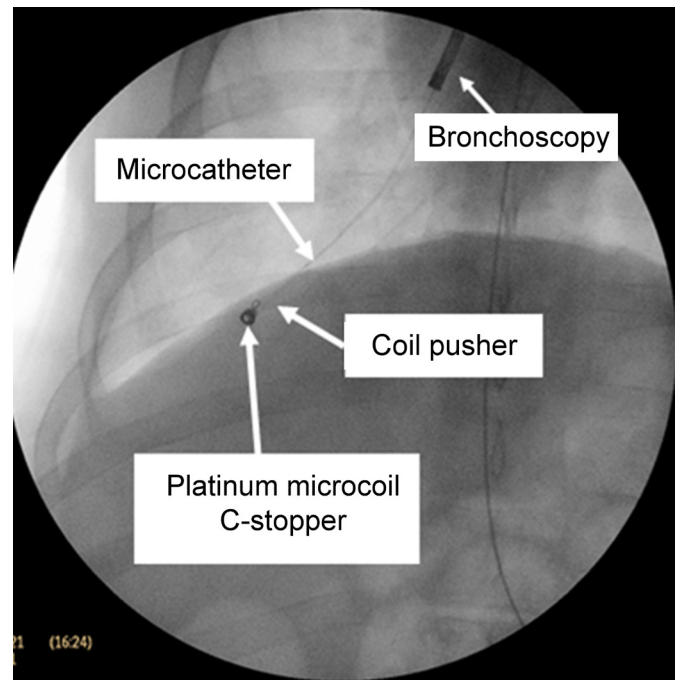


Figure 3 Bronchoscopic marking using microcoils in a 65-year-old woman. Bronchoscopic microcoil placement under fluoroscopy. The arrow labelled 'platinum microcoil (C-stopper)' indicates the microcoils placed in the bronchi.

confident performance of the operation; and grade C, the same operation was judged to be possible without dye marking and microcoil localisation.

Primary outcome

The primary outcome is the rate of successful resection, defined as the number of lesions successfully resected divided by the number of lesions in registered patients that met the eligibility criteria.

Successful resection is defined as excision of the lesion with appropriate margins. Appropriate margins are defined as: (1) the maximum diameter of the tumour when the maximum diameter of the tumour measured on preoperative CT is less than 2 cm, or (2) 2 cm when the maximum diameter of the tumour is 2 cm or more. In addition, successful resection is defined as resections that do not include: (1) change of surgical procedure and/or approach due to inadequate tumour identification or to secure appropriate margins, or (2) incomplete resection due to inadequate tumour identification.

The achievement of successful resection will be judged for the first resection. When it is decided intraoperatively that additional resection is required due to insufficient resection or unsecured margins, the assessment of a successful resection will be made in regard to the first resected specimen. Changes of surgical procedure or approach (thoracoscopy, thoracoscopic aid and chest thoracotomy) due to unsuccessful localisation or insufficient margins will be classified as failure, regardless of the results of additional resections.

Secondary outcomes

The secondary endpoints are: (1) the effectiveness of lung mapping combined with microcoil placement, including the success rate of dye marking, microcoil placement and accurate localisation of the tumour; and (2) the effectiveness of mapping-assisted surgery.

The success rate of dye marking is the proportion of successful dye markings among all the dye markings performed. Successful dye marking is defined as a dye marking that is visually recognisable intraoperatively, with a grade of 1 or higher. The success of microcoil placement is based on whether the microcoils are placed at the planned positions based on *position confirmation* by CT after the mapping procedure. The rate of successful microcoil placement is the proportion of successfully placed microcoils among all the microcoil placements performed. In addition, failure of localisation is defined as incomplete tumour resection or alteration of the surgical approach/procedure to perform an additional resection due to inadequate tumour identification; other cases are classified as accurate localisation.

To assess the effectiveness of mapping-assisted surgery, the following data will be recorded: surgical approach (whether surgery is possible with thoracoscopy alone, or whether palpation via a small thoracotomy is necessary), resection method (whether the tumour is resectable using only the planned resection, or whether extended resection is required), operation time and a survey of the surgeons' opinions regarding the contribution of VAL-MAP 2.0 to the surgery.

Safety assessment

The AEs (defined as any unfavourable or unintended event that affects the patient) will be recorded and categorised into three phases: (1) during the bronchoscopic mapping procedure, (2) after the mapping procedure and before surgery and (3) intraoperatively to postoperative day 30. The causality and severity of AEs will be assessed, with the AEs categorised as 'severe', 'moderate' or 'mild'. Severe AEs are defined in accordance with the definitions of the International Conference on Harmonisation (ICH) safety guideline E2a (death, life-threatening condition, requirement/prolongation of hospitalisation, persistent or substantial disability/incapacity, or congenital anomaly/birth defect) and include other events that cause the discontinuation of planned mapping or surgery. Moderate and mild AEs are defined as AEs from which patients recover with/without any treatment and the planned mapping or surgery is still performed.

Data collection, monitoring and the Data and Safety Monitoring Committee

All data will be collected as electronic data recorded at each institution. An electronic data capture application service (Viedoc, Pharma Consulting Group) will be used for data capturing and management.

The research representative surgeon will conduct monitoring to ensure quality control. The monitoring

will confirm that this research is being conducted in compliance with the latest research plan and regulatory requirements throughout the research period.

The Data and Safety Monitoring Committee (DSMC) will independently review the safety data in the trial monitoring report. The DSMC will consider early termination of the trial if a procedure-related death or serious AE occurs. The DSMC will also monitor protocol compliance, safety and on-schedule study progress.

Sample size

Using the historical data at the University of Tokyo Hospital, the estimated success rate for patients who met the study eligibility criteria and underwent surgery without lung mapping was approximately 52%. Thus, we assumed that a success rate of 60% is a valid threshold to conclude that VAL-MAP using microcoils combined with a multispot dye-marking technique is effective in obtaining sufficient surgical margins in sublobar lung resection. While the success rate of the preceding study of VAL-MAP was 87.7%,¹⁷ after restricting the subjects to those meeting the inclusion criteria of the presently proposed study, the success rate was 78%. The success rate of VAL-MAP 2.0 is expected to be far better than that of surgery without any marking (52%) and slightly better than that with VAL-MAP 1.0 (78%) in this trial population. Therefore, a successful resection rate of 80% was considered to be an appropriate primary endpoint. This estimation was supported by several experts' opinions. Based on the above information, the required sample size was calculated as 60 lesions, with a one-sided type I error rate of 0.025 and a power of 90% to detect an effective success rate of $\geq 80\%$ over an ineffective success rate of $\leq 60\%$, using the Binomial exact test. Assuming a drop out rate of nearly 10% and that some patients may have two lesions, we have set the target sample size as 65.

Statistical analysis

All data analyses will be conducted independently by specialised statisticians in accordance with the study protocol. For the patient characteristics, the data will be expressed as mean \pm SD and median (range) as appropriate. For the primary outcome, the success rate of resection will be assessed, and the 95% CI will be calculated using the exact method. The lower limit of the 95% CI will be used to assess whether the success rate is significantly different from 60%. If the success rate exceeds 60%, this will indicate that VAL-MAP 2.0 is effective in obtaining sufficient surgical margins in sublobar lung resection. Additionally, potential risk factors assumed to affect resection failure will be assessed using a univariate log-binomial regression model. The following parameters will be explored individually: required resection depth, planned operation, Brinkman index, measurement of resection margins on a regular basis in the institution, surgeons' average experience and lesion characteristics. The success rate will be explored via subgroup analysis in

accordance with smoking status, depth of lesion (≥ 2 cm or < 2 cm), location by lung lobe and site.

For each secondary endpoint, evaluating the effectiveness of lung mapping combined with microcoil placement, the success rate and 95% CI will be estimated. The secondary endpoints for the surgical approach and the resection method will also be evaluated by each corresponding rate and 95% CI. The operation time will be expressed as mean \pm SD and median (range).

All reported p values will be two-tailed, and differences with $p < 0.05$ will be considered statistically significant. Statistical analyses will be performed using SAS V.9.4 software.

Ethics and dissemination

This research will be carried out in compliance with the latest version of the Declaration of Helsinki, Clinical Trial Act and related notifications. Results of the primary and secondary endpoints will be submitted for publication in a peer-reviewed journal.

DISCUSSION

With the increasing number of small lung tumours detected via low-dose CT screening, more accurate tumour localisation during video-assisted thoracoscopic surgery has become important for successful resection with sufficient tumour margins. VAL-MAP 2.0 is expected to provide accurate information about tumour depth via the use of indwelling microcoils and surface dye marking. Therefore, VAL-MAP 2.0 can be applied for deeply located small lung tumours that are barely identifiable during surgery to aid in the identification of the resection lines with optimal surgical margins. A strength of VAL-MAP 2.0 is that the tumour margins are attained by resecting microcoil markers that are placed while the lung is naturally deflated, after post-mapping CT has confirmed the anatomical relationship of these markers with the tumour.

As it is unrealistic to compare the VAL-MAP 2.0 technique with a conventional tumour localisation technique or a blinded sham procedure, we will assess the effectiveness of VAL-MAP 2.0 in a non-randomised, unblinded, single-arm study. Although the single-arm design may incur some bias regarding patient selection and outcome evaluation, several strategies will be used to minimise these biases, such as strict eligibility criteria, objectivity in surgical margin measurement and independent assessment of safety data by the DSMC. Furthermore, all participating physicians underwent a mandatory training programme before patient enrolment (including the physicians who had used VAL-MAP in a previous study), which will accelerate the learning curve and minimise technical discrepancies between physicians. Thus, we consider that the results of the proposed trial have been sufficiently internally validated to be used as clinical evidence.

The proposed study will determine whether VAL-MAP 2.0 can contribute to intraoperative tumour localisation to enable accurate resection with sufficient margins, even for small, deeply located, early-stage lung tumours. VAL-MAP 2.0 will potentially contribute to superior outcomes in patients with small malignant pulmonary tumours.

Author affiliations

¹Regulatory strategy Division, Clinical Research Support Center, The University of Tokyo Hospital, Tokyo, Japan

²Biostatistics Division, Clinical Research Support Center, The University of Tokyo Hospital, Tokyo, Japan

³Department of Thoracic Surgery, The University of Tokyo, Graduate School of Medicine, Tokyo, Japan

Acknowledgements We thank Dr Kelly Zammit, BVSc, from Edanz Editing (www.edanzediting.com/ac) for editing a draft of this manuscript. We thank A Okazaki for translating and reviewing the Informed Consent Form.

Contributors All the authors assisted with the development of the protocol, study design and refinement of study materials. KU led the writing of the manuscript. YU is managing the statistical aspects of the trial. MS is managing the whole protocol and the writing of the manuscript. All the authors have been involved in the critical evaluation of the manuscript and approved the final version.

Funding This work was supported by the Japan Agency for Medical Research and Development (grant number: 18ck0106244h0003).

Disclaimer The sponsor was not involved in the study design, data collection, data analysis and interpretation, report writing or decision to submit the paper for publication.

Competing interests None declared.

Patient consent for publication Obtained.

Ethics approval The study was approved by the Clinical Research Review Boards of the University of Tokyo (approval number 218 003SP) for all institutes, and the Technical Review Board for Advanced Medicine Category B of the Ministry of Health, Labour and Welfare.

Provenance and peer review Not commissioned; externally peer reviewed.

Open access This is an open access article distributed in accordance with the Creative Commons Attribution Non Commercial (CC BY-NC 4.0) license, which permits others to distribute, remix, adapt, build upon this work non-commercially, and license their derivative works on different terms, provided the original work is properly cited, appropriate credit is given, any changes made indicated, and the use is non-commercial. See: <http://creativecommons.org/licenses/by-nc/4.0/>.

REFERENCES

1. Siegel RL, Miller KD, Jemal A. Cancer statistics, 2017. *CA Cancer J Clin* 2017;67:7–30.
2. Aberle DR, Adams AM, Berg CD, *et al*. Reduced lung-cancer mortality with low-dose computed tomographic screening. *N Engl J Med* 2011;365:395–409.
3. Finley RJ, Mayo JR, Grant K, *et al*. Preoperative computed tomography-guided microcoil localization of small peripheral pulmonary nodules: a prospective randomized controlled trial. *J Thorac Cardiovasc Surg* 2015;149:26–32.
4. Toba H, Kondo K, Miyoshi T, *et al*. Fluoroscopy-assisted thoracoscopic resection after computed tomography-guided bronchoscopic metallic coil marking for small peripheral pulmonary lesions. *Eur J Cardiothorac Surg* 2013;44:e126–32.
5. Miyoshi T, Kondo K, Takizawa H, *et al*. Fluoroscopy-assisted thoracoscopic resection of pulmonary nodules after computed tomography-guided bronchoscopic metallic coil marking. *J Thorac Cardiovasc Surg* 2006;131:704–10.
6. Iguchi T, Yoshioka T, Muro M, *et al*. Systemic air embolism during preoperative pulmonary marking with a short hook wire and suture system under CT fluoroscopy guidance. *Jpn J Radiol* 2009;27:385–8.
7. Sakiyama S, Kondo K, Matsuoka H, *et al*. Fatal air embolism during computed tomography-guided pulmonary marking with a hook-type marker. *J Thorac Cardiovasc Surg* 2003;126:1207–9.



8. Horan TA, Pinheiro PM, Araújo LM, *et al.* Massive gas embolism during pulmonary nodule hook wire localization. *Ann Thorac Surg* 2002;73:1647–9.
9. Kamiyoshihara M, Sakata K, al ISet. Cerebral arterial air embolism following CT-guided lung needle marking. Report of a case. *J Cardiovasc Surg* 2001;42:699–700.
10. Sato M, Omasa M, Chen F, *et al.* Use of virtual assisted lung mapping (VAL-MAP), a bronchoscopic Multispot dye-marking technique using virtual images, for precise navigation of thoracoscopic sublobar lung resection. *J Thorac Cardiovasc Surg* 2014;147:1813–9.
11. Schuchert MJ, Pettiford BL, Keeley S, *et al.* Anatomic segmentectomy in the treatment of stage I non-small cell lung cancer. *Ann Thorac Surg* 2007;84:926–33.
12. Sawabata N, Ohta M, Matsumura A, *et al.* Optimal distance of malignant negative margin in excision of nonsmall cell lung cancer: a multicenter prospective study. *Ann Thorac Surg* 2004;77:415–20.
13. Goldstein NS, Ferkowicz M, Kestin L, *et al.* Wedge resection margin distances and residual adenocarcinoma in lobectomy specimens. *Am J Clin Pathol* 2003;120:720–4.
14. El-Sherif A, Fernando HC, Santos R, *et al.* Margin and local recurrence after sublobar resection of non-small cell lung cancer. *Ann Surg Oncol* 2007;14:2400–5.
15. Wolf AS, Swanson SJ, Yip R, *et al.* The impact of margins on outcomes after wedge resection for stage I non-small cell lung cancer. *Ann Thorac Surg* 2017;104:1171–8.
16. Sato M, Kuwata T, Yamanashi K, *et al.* Safety and reproducibility of virtual-assisted lung mapping: a multicentre study in Japan†. *European Journal of Cardio-Thoracic Surgery* 2017;42:ezw395–868.
17. Sato M, Kobayashi M, Kojima F, *et al.* Effect of virtual-assisted lung mapping in acquisition of surgical margins in sublobar lung resection. *J Thorac Cardiovasc Surg* 2018;156:1691–701.
18. Sato M, Nagayama K, Kobayashi M, *et al.* Virtual-assisted lung mapping 2.0: preoperative bronchoscopic three-dimensional lung mapping. *Ann Thorac Surg* 2019;(19):30255–3.
19. Lung cancer handling regulations, version 8; The Japan Lung Cancer Society 2017 in Japanese.
20. Sato M, Yamada T, Menju T, *et al.* Virtual-assisted lung mapping: outcome of 100 consecutive cases in a single institute†. *Eur J Cardiothorac Surg* 2015;47:e131–9.